

Low risk of malignancy for small complex adnexal masses

December 17 2014

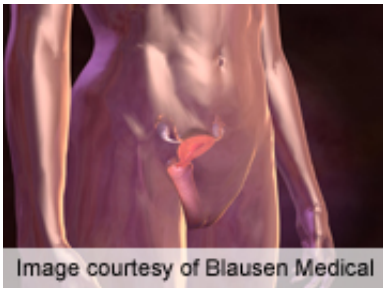


Image courtesy of Blausen Medical

For older women with small complex adnexal masses, the overall risk of malignancy is low, according to a study published in the December issue of the *American Journal of Obstetrics & Gynecology*.

(HealthDay)—For older women with small complex adnexal masses, the overall risk of malignancy is low, according to a study published in the December issue of the *American Journal of Obstetrics & Gynecology*.

Elizabeth Suh-Burgmann, M.D., from the Permanente Medical Group in Walnut Creek, Calif., and colleagues examined outcomes for a large population-based cohort of women older than 50 years with a small (1 to 6 cm) [complex](#) adnexal mass reported on [ultrasound](#). The authors reviewed previous or subsequent pelvic ultrasounds to determine when the mass was first identified and whether there was a change over time. They excluded women with concurrent elevated CA125, evidence of metastatic disease, or less than 24 months of clinical follow-up.

The researchers identified 18 cancers or borderline tumors among 1,363 complex masses (1.3 percent). Among 204 women who had immediate surgery after initial ultrasound (15 percent), six cases were diagnosed; 12 additional cases were identified among 994 women who had at least one repeat ultrasound (73 percent). For all borderline and epithelial ovarian cancers, growth was apparent on ultrasound by seven months. Ten of the 12 cases diagnosed during follow-up were found to be stage 1 at surgery.

"Among isolated adnexal masses reported as complex and 1 to 6 cm on pelvic ultrasound in women older than 50 years, the overall risk of [malignancy](#) is low," the authors write.

More information: [Abstract](#)
[Full Text](#)

Copyright © 2014 [HealthDay](#). All rights reserved.

Citation: Low risk of malignancy for small complex adnexal masses (2014, December 17)
retrieved 21 November 2023 from
<https://medicalxpress.com/news/2014-12-malignancy-small-complex-adnexal-masses.html>

<p>This document is subject to copyright. Apart from any fair dealing for the purpose of private study or research, no part may be reproduced without the written permission. The content is provided for information purposes only.</p>
--