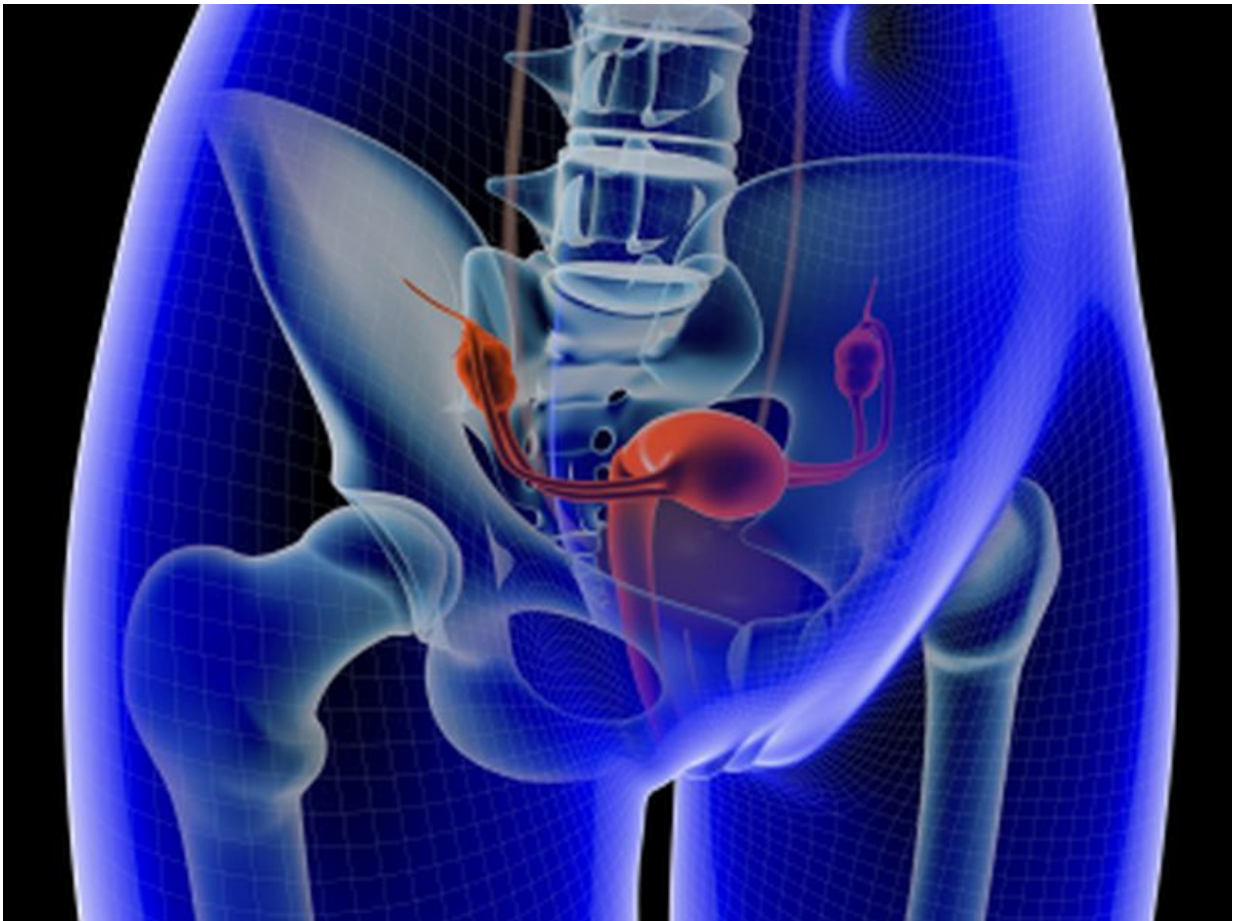


## Case vignette addresses diagnosis, management of PCOS

July 7 2016

---



(HealthDay)—The diagnosis and management of polycystic ovary

syndrome is discussed in a case vignette published online July 6 in *The New England Journal of Medicine*.

Christopher R. McCartney, M.D., and John C. Marshall, M.D., from the University of Virginia School of Medicine, discussed evaluation and management of a 22-year-old woman reporting hirsutism and irregular menses. The symptoms worsened after weight gain in college. On physical examination, her [body mass index](#) was 29 kg/m<sup>2</sup> and [blood pressure](#) was 135/85 mmHg; she had moderate hirsutism without virilization.

The researchers note that since the patient had hyperandrogenism and oligomenorrhea, ovarian ultrasound was not necessary for a diagnosis of polycystic ovary syndrome. Treatment decisions should be informed by patient priorities, with hirsutism and irregular menses the primary concerns for this patient. In the absence of contraindication, a monophasic combined oral contraceptive with a low androgenic progestin was recommended; treatment would improve hirsutism, provide predictable withdrawal bleeding, and prevent endometrial hyperplasia. Clinical assessment at three months should include blood pressure and fasting lipid assessments. Additional pharmacologic therapy could include spironolactone for hirsutism, metformin for abnormal glucose tolerance, and clomiphene for ovulation induction.

"The patient can be counseled that live birth can be achieved by a majority of women with the [polycystic ovary syndrome](#), although fertility treatment may be required," the authors write.

One author disclosed financial ties to the pharmaceutical industry.

**More information:** [Full Text \(subscription or payment may be required\)](#)

Copyright © 2016 [HealthDay](#). All rights reserved.

Citation: Case vignette addresses diagnosis, management of PCOS (2016, July 7) retrieved 19 November 2023 from

<https://medicalxpress.com/news/2016-07-case-vignette-diagnosis-pcos.html>

This document is subject to copyright. Apart from any fair dealing for the purpose of private study or research, no part may be reproduced without the written permission. The content is provided for information purposes only.