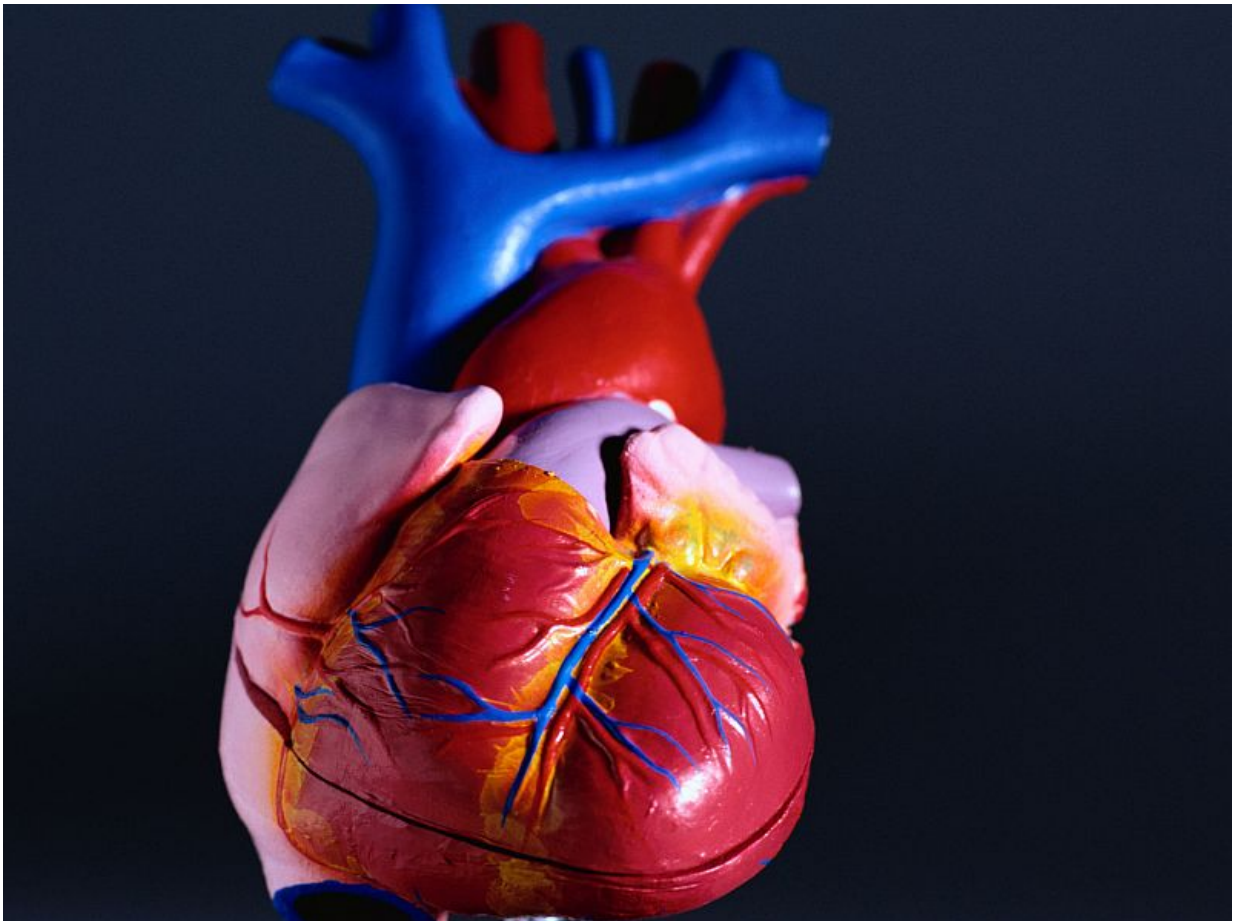


CT colonography may be useful for aneurysm detection

October 4 2016



(HealthDay)—Routine assessment of the aorta during a computed

tomography colonography (CTC) may aid in aneurysm detection, according to a study published online Sept. 21 in the *Journal of Medical Imaging and Radiation Oncology*.

Manar Khashram, M.B.Ch.B., from Christchurch Hospital in New Zealand, and colleagues sought to determine the impact that CTC had on small aneurysm referrals and to compare baseline characteristics of those referred by CTC with those referred by other radiological modalities.

The researchers found that 96 of the 566 consecutive patients with small aneurysms (17 percent) had their aneurysm detected by CTC. The rest of the patients with small aneurysms had them detected by other radiological modalities. Patients with small aneurysms detected by CTC were two years older, on average, and were less likely to have a smoking history.

"Despite a potential selection bias for patients undergoing CTC, there were no major baseline differences between the CTC cohort and patients referred by other radiological modalities," the authors write.

More information: [Abstract](#)
[Full Text \(subscription or payment may be required\)](#)

Copyright © 2016 [HealthDay](#). All rights reserved.

Citation: CT colonography may be useful for aneurysm detection (2016, October 4) retrieved 6 April 2024 from <https://medicalxpress.com/news/2016-10-ct-colonography-aneurysm.html>

<p>This document is subject to copyright. Apart from any fair dealing for the purpose of private study or research, no part may be reproduced without the written permission. The content is provided for information purposes only.</p>
--