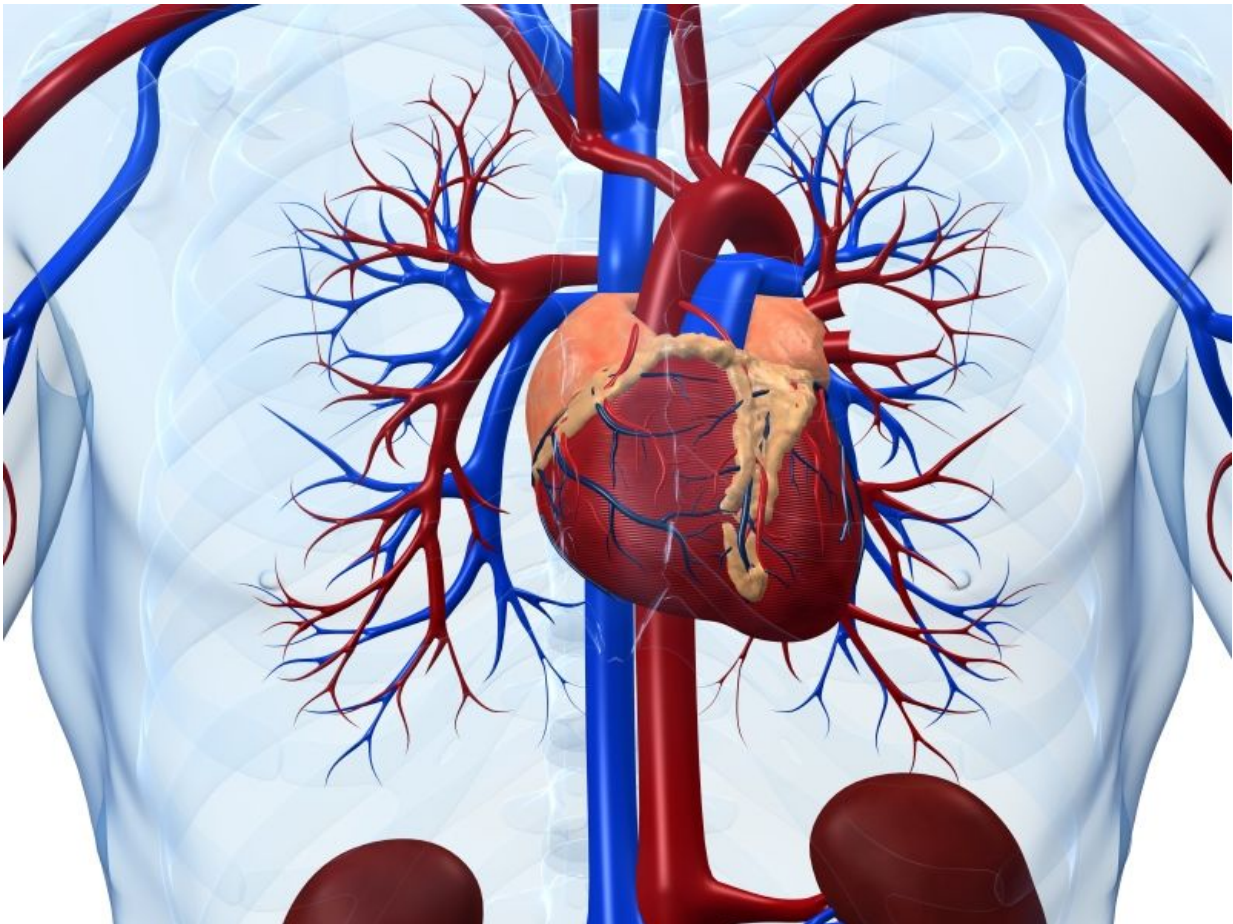


Ipsilateral ulnar compression cuts radial artery occlusion

October 5 2016



(HealthDay)—Radial artery occlusion (RAO) after transradial access

(TRA) can be cut significantly with prophylactic ipsilateral ulnar compression, according to a study published in the Oct. 10 issue of *JACC: Cardiovascular Interventions*.

Samir B. Pancholy, M.D., from Commonwealth Medical College in Scranton, Pa., and colleagues randomized 3,000 patients undergoing diagnostic cardiac catheterization using TRA to either standard patent hemostasis protocol or prophylactic ipsilateral ulnar compression in addition to patent hemostasis. Radial artery patency was evaluated using plethysmography at the time of removal of the [compression device](#) as well as 24 hours and 30 days after the procedure.

The researchers found that RAO was significantly reduced in patients with patent hemostasis and prophylactic ulnar compression versus standard patent hemostasis (0.9 versus 3.0 percent; $P = 0.0001$). RAO reduction was significant at all time intervals (P

"Prophylactic ipsilateral ulnar compression during radial artery hemostasis is an effective, simple, and inexpensive technique that lowers the risk of RAO after TRA," the authors write.

One author disclosed financial ties to the medical device industry.

More information: [Full Text \(subscription or payment may be required\)](#)
[Editorial \(subscription or payment may be required\)](#)

Copyright © 2016 [HealthDay](#). All rights reserved.

Citation: Ipsilateral ulnar compression cuts radial artery occlusion (2016, October 5) retrieved 5 May 2023 from <https://medicalxpress.com/news/2016-10-ipsilateral-ulnar-compression-radial-artery.html>

This document is subject to copyright. Apart from any fair dealing for the purpose of private study or research, no part may be reproduced without the written permission. The content is provided for information purposes only.