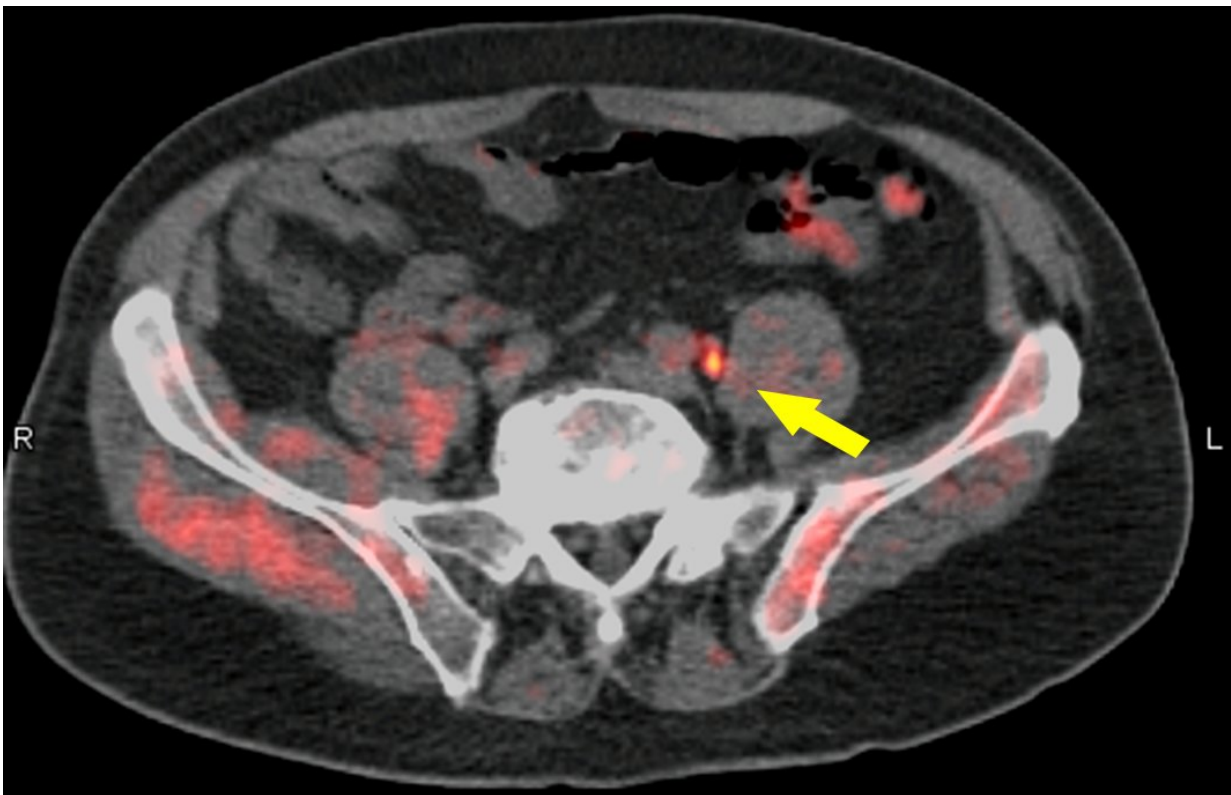


Fluciclovine PET/CT locates recurrent prostate cancer and advises management

June 26 2018



The addition of fluorine-18 (¹⁸F)-fluciclovine positron emission tomography/computed tomography (PET/CT) to the diagnostic work-up of patients with biochemical recurrence of prostate cancer locates previously undetected lesions and changes treatment management for the majority of patients, according to a clinical trial report presented at the 2018 Annual Meeting of the Society of Nuclear Medicine and Molecular Imaging (SNMMI). Credit: Barry A. Siegel MD, Division of Nuclear Medicine, Mallinckrodt Institute of Radiology and the Alvin J. Siteman Cancer Center, Washington University School of Medicine, St. Louis, MO.

The addition of fluorine-18 (^{18}F)-fluciclovine positron emission tomography/computed tomography (PET/CT) to the diagnostic work-up of patients with biochemical recurrence of prostate cancer locates previously undetected lesions and changes treatment management for the majority of patients, according to a clinical trial report presented at the 2018 Annual Meeting of the Society of Nuclear Medicine and Molecular Imaging (SNMMI).

"Recurrent [prostate cancer](#) poses an important medical challenge," explains Austin R. Pantel, MD, of the University of Pennsylvania in Philadelphia. "Currently approved anatomical imaging procedures have limitations in identifying the sites of recurrence of [prostate cancer](#) after definitive treatment. This can make decision-making difficult when assessing these patients." He notes, "Up to 30 percent of patients with prostate cancer will develop local or distant recurrence within 10 years of radical prostatectomy or radiation therapy. Determining the location and extent of recurrent disease optimizes the selection of appropriate management for these men."

For the LOCATE trial (ID# NCT02680041), 213 men with biochemically recurrent prostate cancer were evaluated with ^{18}F -fluciclovine PET/CT after having negative or equivocal findings on conventional imaging, such as a bone scan, CT or magnetic resonance imaging (MRI). This first prospective multicenter study was conducted at 15 sites in the U.S., including both private practices and academic settings. It focused on the association between scan positivity and the clinical variables of recurrence site, practice setting, prostate-specific antigen (PSA) level, and Gleason score (system of grading prostate cancer). Questionnaires completed by treating physicians documented changes in management after the PET study.

Trial results showed that 59 percent (126/213) of [patients](#) had their clinical management changed by findings from ^{18}F -fluciclovine imaging. Of those changes, 78 percent (98/126) were classified as "major" (i.e., a change in treatment modality). Disease was detected in the prostate, as well as other tissue, including pelvic and abdominal lymph nodes and, less commonly, bone. Both positive and negative scans impacted patient management. No difference was seen in the rate of positive scans or in the rate of management changes between private practices and academic settings. In addition, no association was found between Gleason score at diagnosis and positive scans.

Pantel points out, "While investigation of the long-term clinical outcomes of these changes in management is warranted, these results indicate, for the first time in a prospective U.S. study, that decisions based on ^{18}F -fluciclovine PET/CT imaging may facilitate more appropriate management in men with biochemical recurrence of their prostate cancer. The study also demonstrates the broad potential applicability of ^{18}F -fluciclovine PET/CT imaging across a range of clinical settings."

He emphasizes, "Selecting appropriate treatment for men with recurrent prostate cancer is critical. Many options are available, and additional information, such as that provided by ^{18}F -fluciclovine PET/CT, may help tailor personalized treatment plans. Clinical studies, such as the LOCATE trial, are important to investigate the role of the current generation of molecular imaging agents in guiding management for men with recurrent prostate cancer. This study highlights the key role of nuclear medicine in directing effective patient [management](#) and care."

More information: Abstract 457: " ^{18}F -Fluciclovine PET/CT in patients with biochemical recurrence of prostate cancer: Impact on management and associations of clinical variables with scan findings," Austin R. Pantel, MD, Eleanor Gillis, MD, and David A. Mankoff, MD,

PhD, University of Pennsylvania, Philadelphia, PA; and Barry A. Siegel, MD, Mallinckrodt Institute of Radiology. St. Louis, MO, SNMMI's 65th Annual Meeting, June 23-26, Philadelphia.

[jnm.snmjournals.org/content/59 ... 54-b2f3-39bf6ce31139](http://jnm.snmjournals.org/content/59...54-b2f3-39bf6ce31139)

Provided by Society of Nuclear Medicine and Molecular Imaging

Citation: Fluciclovine PET/CT locates recurrent prostate cancer and advises management (2018, June 26) retrieved 19 November 2023 from

<https://medicalxpress.com/news/2018-06-fluciclovine-petct-recurrent-prostate-cancer.html>

This document is subject to copyright. Apart from any fair dealing for the purpose of private study or research, no part may be reproduced without the written permission. The content is provided for information purposes only.