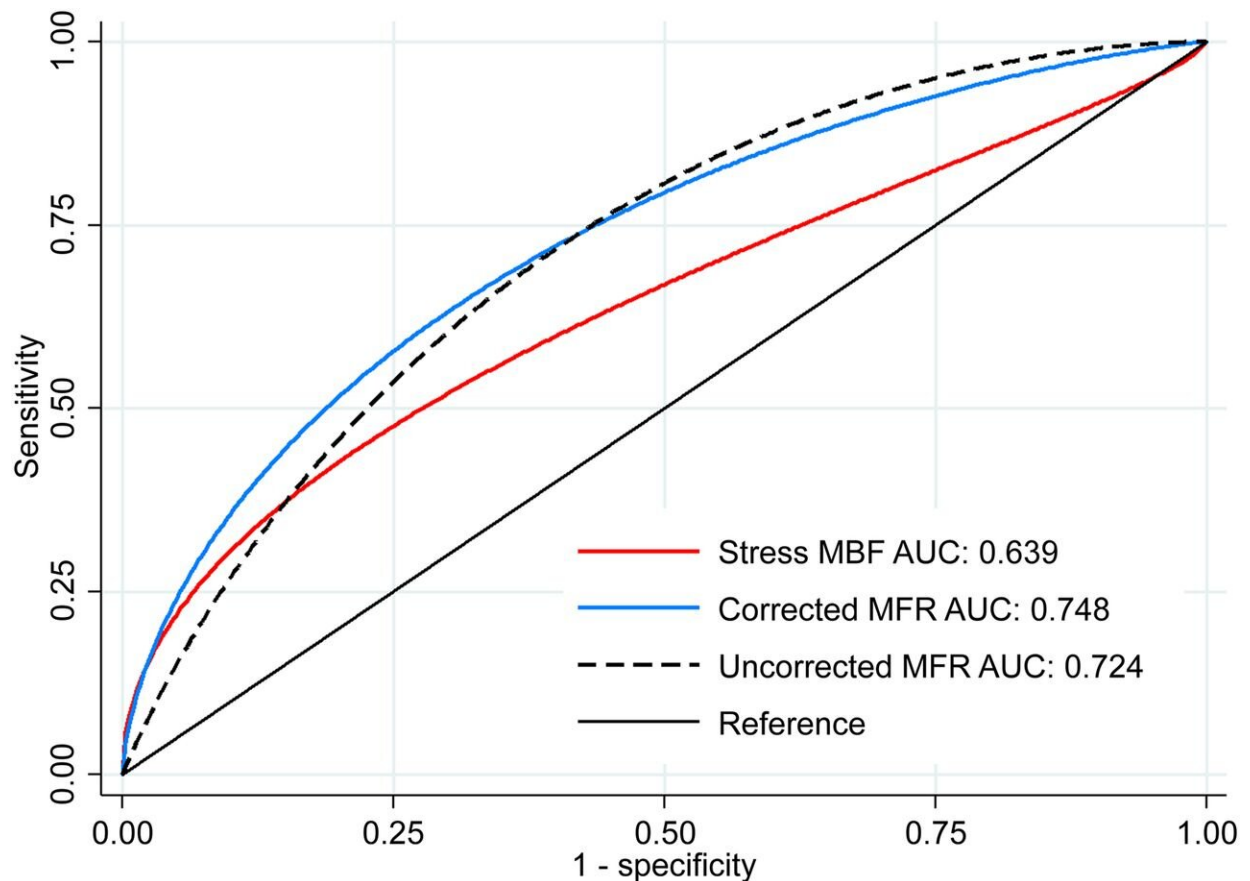


# PET imaging offers new insights into post-transplant care for heart patients

March 5 2020



Receiver-operating-characteristic curves for identifying all-cause mortality during follow-up. Uncorrected MFR AUC was significantly larger than stress MBF AUC ( $P = 0.047$ ). There was no significant difference between uncorrected MFR AUC and corrected MFR AUC ( $P = 0.681$ ). Society of Nuclear Medicine and Molecular Imaging

Myocardial blood flow (MBF) and myocardial flow reserve (MFR) have been identified as accurate indicators for graft failure after cardiac transplantation, according to a new study published in *The Journal of Nuclear Medicine*. Utilizing positron emission tomography (PET) myocardial perfusion imaging to quantify MBF and MFR, researchers were able to successfully detect patients with cardiac allograft vasculopathy (CAV), the most serious condition facing transplant patients late after their surgery. In addition, researchers found that MFR had a significantly higher accuracy when predicting the overall prognosis for cardiac transplant patients.

Heart transplantation is a definitive therapy for patients with end-stage heart failure and has a median post-transplant survival of more than 13 years. As [long-term survival](#) has increased, the prevalence of cardiac diseases, such as CAV, has also grown. CAV accounts for over one-third of deaths in patients who survive at least five years after their heart transplant. It is also the most common indication for re-transplantation in patients who survive one year.

"MBF and MFR have been shown to be useful for diagnosis and prognosis of CAV in a few single-center studies, however, there is no consensus on which marker—stress MBF or MFR—should be applied for these purposes," said Robert J.H. Miller, MD, FRCPC, clinical assistant professor at the University of Calgary in Canada. "In this study, we compared the utility of MBF and MFR, using previously derived thresholds, to provide the external validation required to guide broader clinical implementation."

Ninety-nine cardiac transplant patients who underwent  $^{82}\text{Rb}$  PET [myocardial perfusion](#) imaging over a five-year period in a single center were included in the study. Quantitative and semi-quantitative analyses were performed and imaging parameters were compared among study participants who died (26 patients) and those who survived (73 patients).

Researchers then examined the diagnostic and prognostic accuracy for MBR and MFR in detecting significant CAV.

Results from the study demonstrated that stress MBF, uncorrected MFR and corrected MFR were equivalent in identifying patients with significant CAV. In terms of prognosis, researchers found that uncorrected MFR offered superior discrimination for mortality of all causes compared to stress MBF. Further, the study found that preserved MFR (defined as greater than or equal to 2.0) identified low-risk patients, while the presence of multiple abnormal parameters identified patients at the highest risk.

"PET with routine measures of MBF and MFR has a clear role in [patients](#) following [cardiac transplantation](#). This study provides practical information for centers implementing PET for CAV surveillance and will help guide them in implementing these important measurements" noted Miller.

**More information:** Robert J.H. Miller et al, Comparative Prognostic and Diagnostic Value of Myocardial Blood Flow and Myocardial Flow Reserve After Cardiac Transplantation, *Journal of Nuclear Medicine* (2019). [DOI: 10.2967/jnumed.119.229625](https://doi.org/10.2967/jnumed.119.229625)

Provided by Society of Nuclear Medicine and Molecular Imaging

Citation: PET imaging offers new insights into post-transplant care for heart patients (2020, March 5) retrieved 22 February 2024 from <https://medicalxpress.com/news/2020-03-pet-imaging-insights-post-transplant-heart.html>

This document is subject to copyright. Apart from any fair dealing for the purpose of private study or research, no part may be reproduced without the written permission. The content is provided for information purposes only.