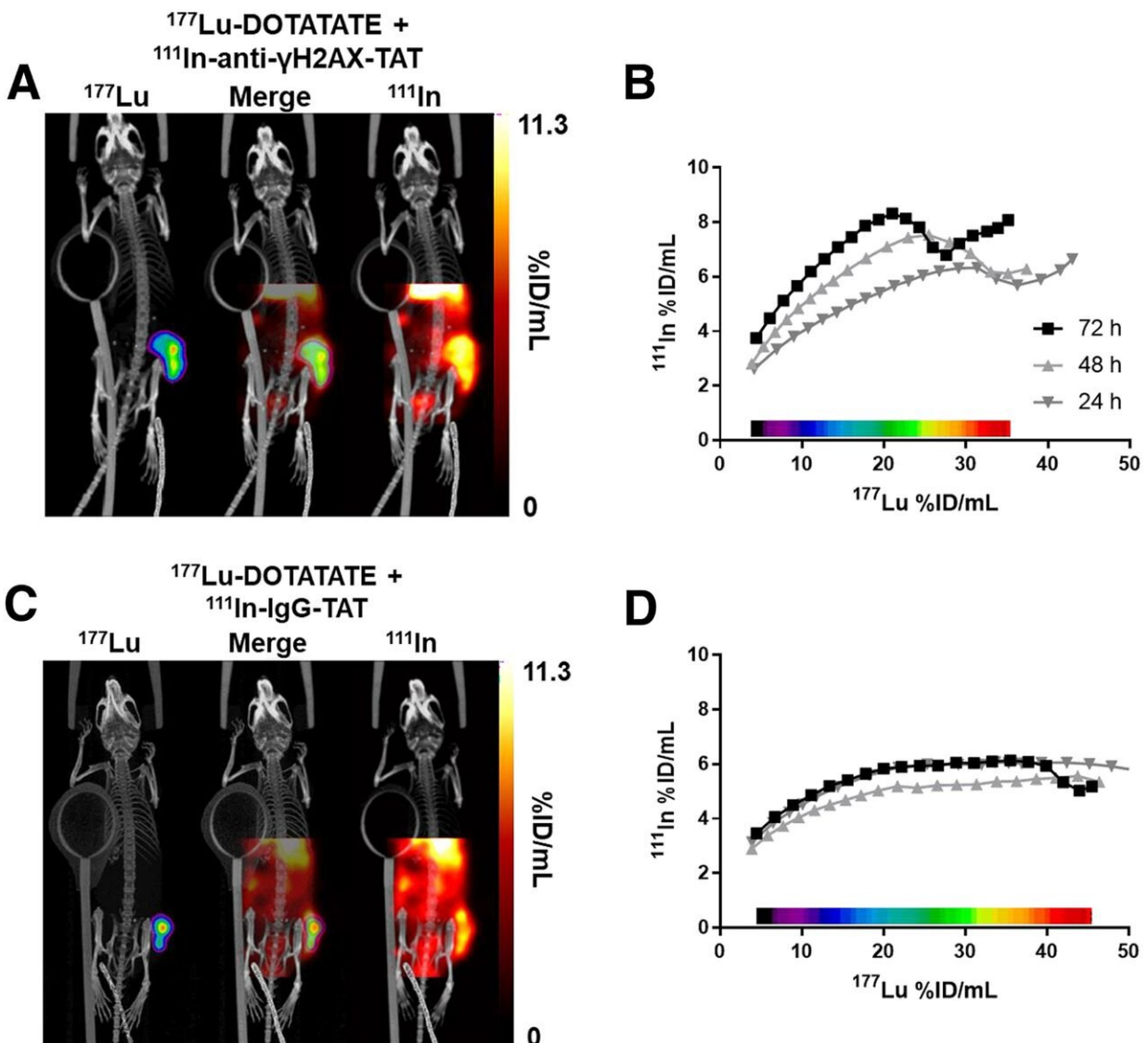


Molecular imaging offers insight into therapy outcomes for neuroendocrine tumor patients

May 14 2020



(A) Representative dual-isotope SPECT/CT images of mice 71 h after intravenous administration of ^{111}In -anti- γH2AX -TAT (5 MBq, 5 μg) and 72 h

after intravenous administration of ^{177}Lu -DOTATATE (20 MBq, 0.33 μg). Tumor is indicated by purple contour in ^{177}Lu image. (B) Correlation between ^{111}In and ^{177}Lu signal in tumor volume in voxel collections based on ^{177}Lu signal quantification in SPECT image of animal in A. (C) Representative dual-isotope SPECT/CT images of mice after administration of ^{111}In -IgG-TAT (5 MBq, 5 μg) and ^{177}Lu -DOTATATE (20 MBq, 0.33 μg). Tumor is indicated by purple contour in ^{177}Lu image. (D) Correlation between ^{111}In and ^{177}Lu signal in tumor volume in voxel collections based on ^{177}Lu signal quantification in SPECT image of animal in C. Credit: Society of Nuclear Medicine and Molecular Imaging

A new proof-of-concept study published in the May issue of *The Journal of Nuclear Medicine* has demonstrated that molecular imaging can be used for identifying early response to ^{177}Lu -DOTATATE treatment in neuroendocrine tumor patients.

Utilizing single photon emission computed tomography (SPECT) imaging with ^{111}In -anti γH2AX -TAT, researchers were able to visualize a DNA damage response marker just days after ^{177}Lu -DOTATATE treatment. Monitoring the DNA damage response in the early days after the radionuclide injection could allow physicians to determine the therapeutic outcome and adapt the therapy regimen accordingly.

The radiobiologic aspects of ^{177}Lu -DOTATATE, as well as other molecular radiotherapies, are underexplored. Radionuclide therapy is largely delivered to neuroendocrine [tumor](#) patients on a fixed dose protocol, regardless of body weight or tumor uptake. To justify any increase or decrease in the prescribed radionuclide dose a sustainable metric is needed; however, no metric currently exists.

"One strategy to develop this metric is to determine if sufficient damage has been afflicted to the tumor, which would allow treating physicians to

tailor subsequent doses to ensure therapeutic success," said Bart Cornelissen, Ph.D., associate professor in the department of oncology at the MRC Oxford Institute for Radiation Oncology at the University of Oxford in Oxford, United Kingdom. "In our study, we sought to image the molecular biological effects of ^{177}Lu -DOTATATE radionuclide therapy by visualizing the DNA double-strand break damage response marker γH2AX ."

In the study, researchers first exposed six cell lines to external beam therapy or ^{177}Lu -DOTATATE and measured the number of γH2AX foci and the clonogenic survival (which indicate the extent of DNA double-strand break damage). Mice bearing the same cell line were then treated with ^{177}Lu -DOTATATE or sham-treated, and static SPECT images were acquired at one, 24, 48 and 72 hours after administration. Immediately after the first SPECT imaging session, the mice were administered ^{111}In -anti- γH2AX -TAT or ^{111}In -IgG-TAT.

In vitro [cell lines](#) exposed to ^{177}Lu -DOTATATE were found to have increased γH2AX foci and decreased clonogenic survival, and reacted very differently than to an equitoxic dose of external beam irradiation. The γH2AX foci induced by ^{177}Lu -DOTATATE in the preclinical models were successfully imaged by SPECT in vivo using ^{111}In -anti- γH2AX -TAT. An accumulation of γH2AX signal was observed over the days after administration of ^{177}Lu -DOTATATE, indicating an increase in DNA damage. Furthermore, γH2AX expression revealed intratumoral and interlesion heterogeneity with the absorbed ^{177}Lu dose, suggesting that different parts of the tumor may react differentially to treatment with ^{177}Lu -DOTATATE.

"The application of this imaging technique could provide a very early indicator of tumor damage without having to wait for changes in tumor volume, which currently may take months to find out," noted Edward O'Neill, postdoctoral researcher in the department of oncology at MRC

Oxford Institute for Radiation Oncology at the University of Oxford in Oxford, United Kingdom. "When using therapeutic response assessment with [molecular imaging](#), making rapid decisions becomes possible, including dose reduction to avoid side effects, assessment of combination therapies, or, in the absence of any measurable response, initiation of palliative options designed toward improving quality of life."

More information: Edward O'Neill et al, Imaging DNA Damage Repair In Vivo After ¹⁷⁷Lu-DOTATATE Therapy, *Journal of Nuclear Medicine* (2020). [DOI: 10.2967/jnumed.119.232934](https://doi.org/10.2967/jnumed.119.232934)

Provided by Society of Nuclear Medicine and Molecular Imaging

Citation: Molecular imaging offers insight into therapy outcomes for neuroendocrine tumor patients (2020, May 14) retrieved 2 May 2023 from <https://medicalxpress.com/news/2020-05-molecular-imaging-insight-therapy-outcomes.html>

This document is subject to copyright. Apart from any fair dealing for the purpose of private study or research, no part may be reproduced without the written permission. The content is provided for information purposes only.