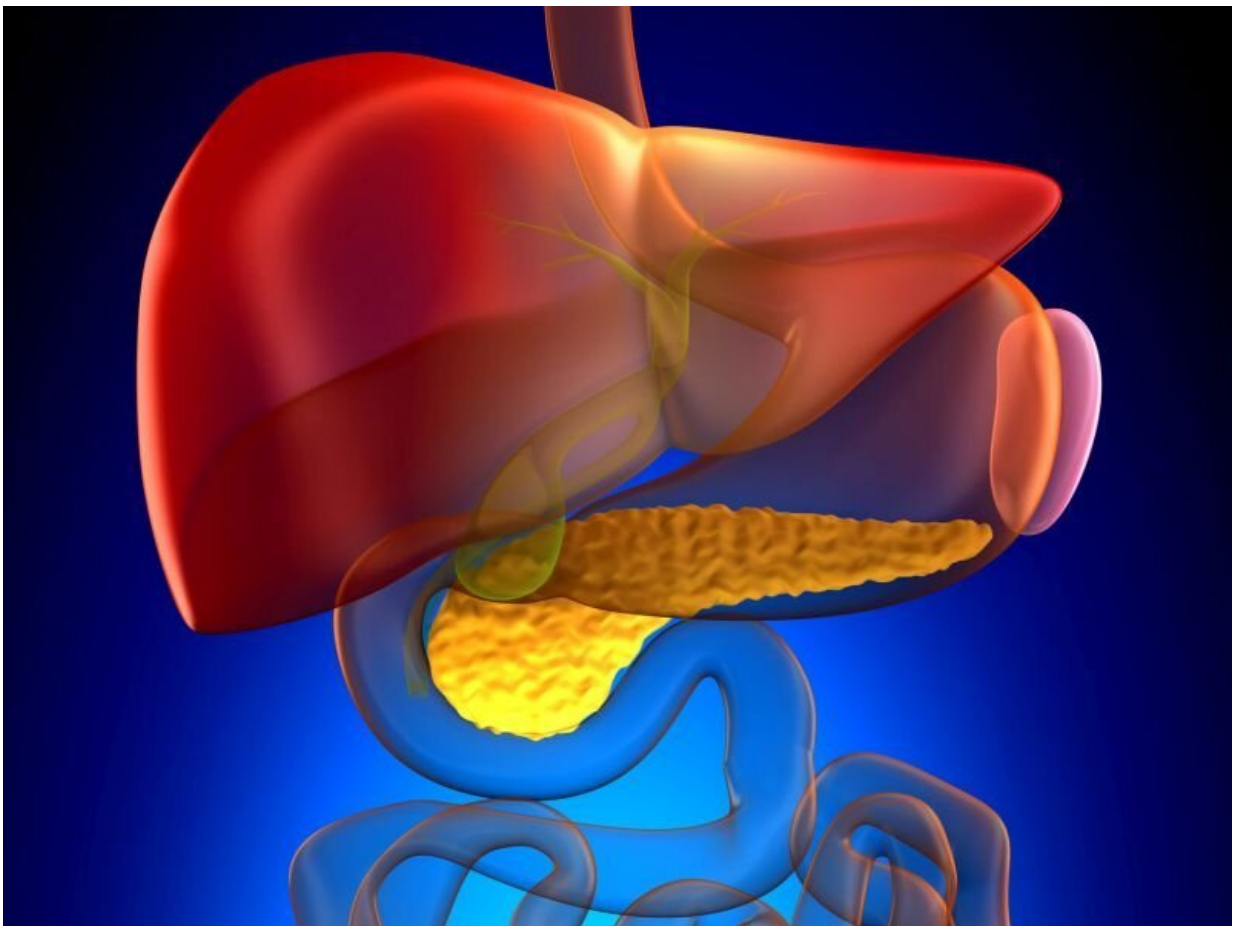


Endoscopic ultrasound-guided drainage studied in noncholecystitis gallbladder disease

February 1 2022



(HealthDay)—For patients with noncholecystitis (NC) gallbladder disease who are poor surgical candidates, endoscopic ultrasound-guided transluminal gallbladder drainage (EUS-GBD) appears to be safe and effective for managing gallstone disease, according to a study recently published in *Endoscopic Ultrasound*.

Duncan J. Flynn, M.D., from Massachusetts General Hospital in Boston, and colleagues examined outcomes for EUS-GBD using data from a quaternary academic hospital for endoscopic procedures from 2015 to 2020. Data were included for 56 patients who underwent EUS-GBD for acute cholecystitis and NC indications, including biliary colic, gallstone pancreatitis, and secondary prevention of [gallstone disease](#).

The researchers found that 41 interventions were performed for [acute cholecystitis](#), and 15 were performed for NC indications, including primary treatment of symptomatic biliary colic and secondary prevention of gallstone pancreatitis and choledocholithiasis. No statistically significant differences in complications, mortality, or reintervention requirements were seen between the groups. The rate of immediate complications was 13.3 percent in the NC group, which were all managed medically; the rate in the cholecystitis group was 14.6 percent, all of which were managed medically or endoscopically, without need for [surgical intervention](#).

"EUS-GBD remains an emerging treatment for gallbladder disease in nonoperative candidates," the authors write. "Our study is the first to demonstrate safety and technical success in NC cases."

More information: [Abstract/Full Text](#)

Copyright © 2021 [HealthDay](#). All rights reserved.

Citation: Endoscopic ultrasound-guided drainage studied in noncholecystitis gallbladder disease (2022, February 1) retrieved 28 February 2023 from <https://medicalxpress.com/news/2022-02-endoscopic-ultrasoundguided-drainage-noncholecystitis-gallbladder.html>

This document is subject to copyright. Apart from any fair dealing for the purpose of private study or research, no part may be reproduced without the written permission. The content is provided for information purposes only.