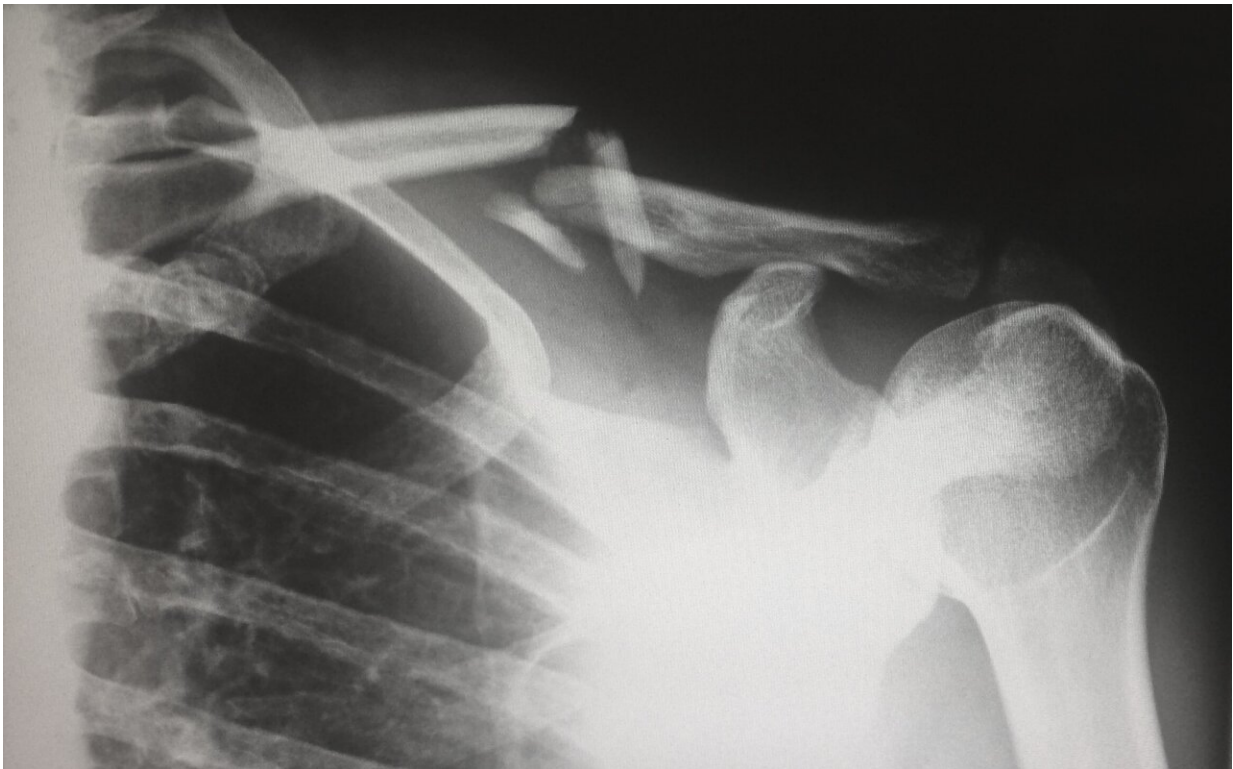


How orthopedic surgeons fix your shoulder when it's injured

March 30 2022, by Lauren Woods



Credit: Unsplash/CC0 Public Domain

Ever hear of your glenohumeral joint? Probably not.

But it is the critical ball-and-socket joint helping you use your [shoulder](#) daily. In fact, the shoulder is most mobile joint in your body. However,

the joint's increased mobility also makes it the most unstable and commonly dislocated.

The shoulder joint is comprised of the socket, which looks like a golf tee, and the upper part of the arm, the humeral head, which looks like a golf ball. Injury to shoulder [ligaments](#) and labrum can often render the shoulder joint unstable. Plus, multiple dislocations can wear away the glenoid, much like losing the edge of a golf tee. This bone loss makes the shoulder even more unstable.

"Bone loss is a very significant part of the problem," says UConn School of Medicine's Chief of the Division of Sports Medicine Dr. Robert Arciero, who was in the military early in his medical career, where he first learned that shoulder instability is actually more prevalent than ACL knee injuries.

The amount of bone loss a patient has in their shoulder actually changes the surgery a patient requires. Also, if bone loss in the shoulder joint is not treated, it can lead to failure after a less invasive procedure, such as an arthroscopic repair.

Coracoid bone graft transfer has been the gold standard used by orthopedic surgeons to address bone loss and to stabilize the shoulder joint. The coracoid is a local graft in the shoulder, taking a piece of a patient's own shoulder blade and transferring it to the front of their shoulder socket. This longstanding technique helps hold the ball in the socket of the shoulder joint to stop the joint's future dislocation.

While other alternative bone transfer techniques using a patient's own localized bones have been used, Arciero and colleagues concluded in the March issue of the *American Journal for Sports Medicine* that coracoid transfer remains the most reliable restorative bone graft option for shoulder surgery repair. Also, it is the only technique capable of filling a

large glenoid joint defect of up to 40%. In the study, the researchers stratified the percentage of bone loss that can be restored by each of the three localized bone grafts techniques for shoulder surgery repair: coracoid, distal clavicle and scapular spine.

"This is first time in literature that we have compared three local autografts," says Arciero and co-researchers who report one technique still has the strongest advantage.

"The history," says Arciero, regarding the coracoid bone graft. "This option was invented or described in 1954. That means there is almost 70 years of clinical data on its use. That's a huge advantage to using the coracoid. It works. But there is a steep learning curve."

He adds, "As far as coracoid, our study results match previous research work."

The research team looks forward to more clinical data becoming available over time for the other alternative bone [graft](#) techniques currently leveraged by orthopedic surgeons.

According to Arciero, the new study findings are a true game changer for orthopedic surgeons, and even his own surgical practice.

"The coracoid can be used for larger glenoid bone defects. That's the take home message that's changing my practice," says Arciero. "We found that you can definitely go up to 30 percent [for a glenoid defect repair need] and still achieve sufficient solution to the glenoid bone loss with just the coracoid."

More information: Santiago Rodriguez et al, Comparison of the Coracoid, Distal Clavicle, and Scapular Spine for Autograft Augmentation of Glenoid Bone Loss: A Radiologic and Cadaveric

Assessment, *The American Journal of Sports Medicine* (2022). DOI: [10.1177/03635465211065446](https://doi.org/10.1177/03635465211065446)

Provided by University of Connecticut

Citation: How orthopedic surgeons fix your shoulder when it's injured (2022, March 30)
retrieved 20 February 2023 from <https://medicalxpress.com/news/2022-03-orthopedic-surgeons-shoulder.html>

This document is subject to copyright. Apart from any fair dealing for the purpose of private study or research, no part may be reproduced without the written permission. The content is provided for information purposes only.