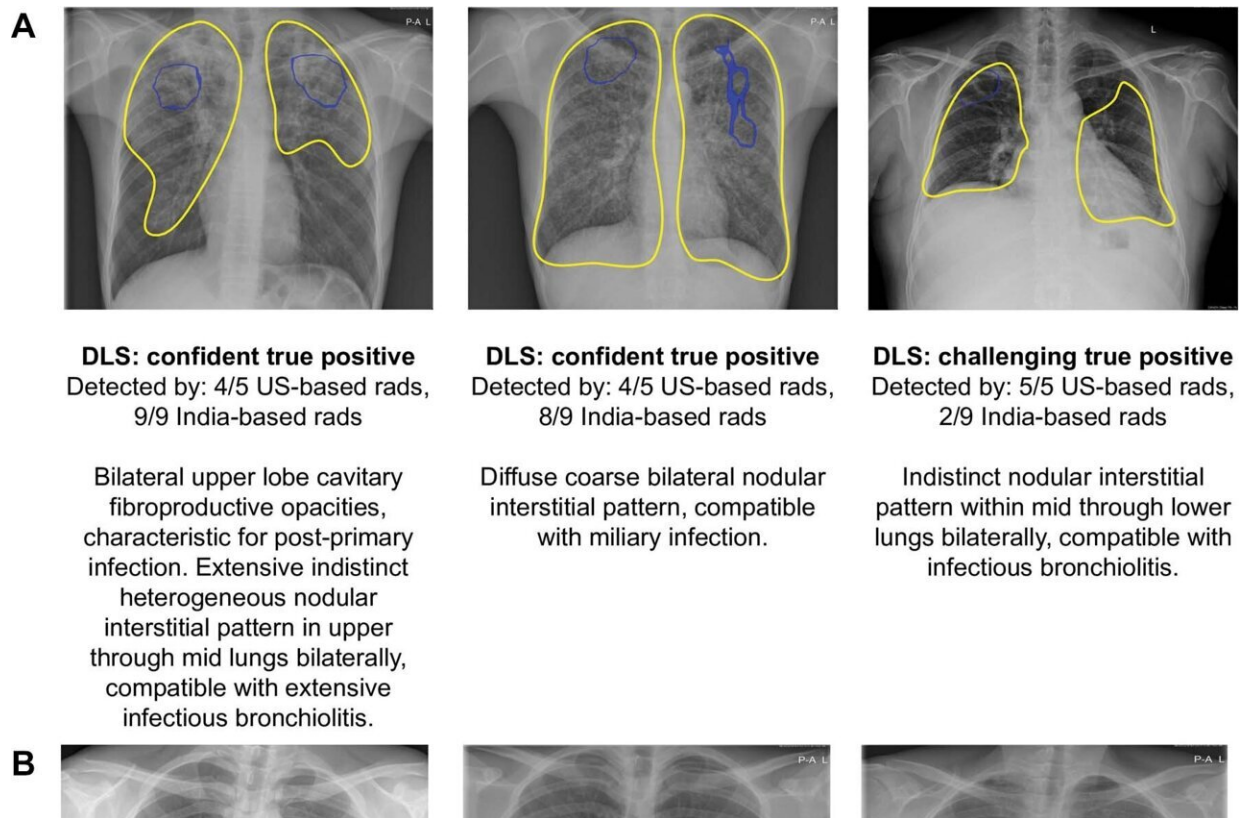


AI-based system shows promise in tuberculosis detection

September 13 2022



Examples of chest radiographs for which the deep learning system (DLS) provided the correct interpretation, corresponding to (A) tuberculosis (TB)-positive subjects and (B) TB-negative subjects. Blue outlines encircle salient regions via Grad-CAM (35) that most influence the positive prediction from the DLS and are shown when the DLS considered the image positive. Yellow outlines were annotated by a radiologist to indicate regions of interest; solid outlines indicate findings consistent with TB while dotted outlines indicate other findings. “Confident” indicates that the DLS predicted values close to 0 or

1, whereas “challenging” indicates that the DLS predicted values close to the operating point (0.45). CXR = chest radiograph, rads = radiologists. Credit: Radiological Society of North America

An artificial intelligence (AI) system detects tuberculosis (TB) in chest X-rays at a level comparable to radiologists, according to a study published in *Radiology*. Researchers said the AI system may be able to aid screening in areas with limited radiologist resources.

TB is an infectious disease of the lungs that kills more than a million people worldwide every year. The COVID-19 pandemic has exacerbated the problem, with recent reports indicating that 21% fewer people received care for TB in 2020 than in 2019. Almost 90% of the active TB infections occur in about 30 countries, many with scarce resources needed to address this public health problem.

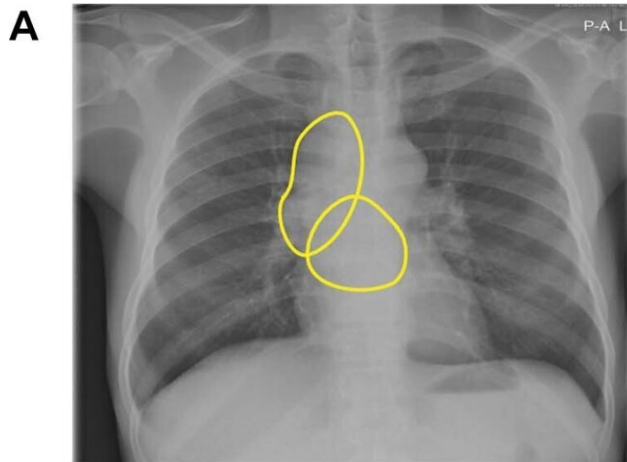
"We have effective drugs for treating TB, but large-scale screening programs to detect TB are not always feasible in [low-income countries](#) due to cost and availability of expert radiologists," said study co-author Rory Pilgrim, B.Eng., a product manager at Google Health AI in Mountain View, California.

Cost-effective TB screening using chest X-rays and AI has the potential to improve access to healthcare, Pilgrim said, particularly in difficult-to-reach populations.

"Bridging the expert shortage is where AI comes in," said first author Sahar Kazemzadeh, B.S., software engineer at Google Health. "We can teach computers to recognize tuberculosis from X-rays so that in these [low-resource settings](#) a patient's X-ray can be interpreted within seconds."

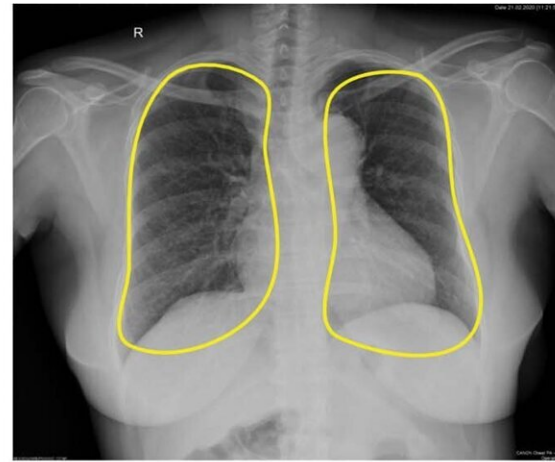
Kazemzadeh and colleagues developed and assessed an AI system that can quickly and automatically evaluate chest X-rays for TB. The system uses [deep learning](#), a type of AI that can be applied to teach the computer to recognize and predict medical conditions. The researchers developed the system using data from nine countries. They then tested it on data from five countries, covering multiple high-TB-burden countries, various clinical settings and a wide range of races and ethnicities. Over 165,000 images from more than 22,000 patients were used for model development and testing.

Analysis with 14 international radiologists showed that the deep-learning method was comparable to radiologists for the determination of active TB on chest X-rays.



DLS: challenging false negative
 Detected by: 5/5 US-based rads,
 1/9 India-based rads

Bulky right mediastinal, right hilar,
 and subcarinal masses, compatible
 with multifocal lymphadenopathy.



DLS: challenging false negative
 Detected by: 4/5 US-based rads,
 3/9 India-based rads

Diffuse fine bilateral nodular
 interstitial pattern, compatible with
 miliary infection.

Examples of chest radiographs for which the deep learning system (DLS)

provided the wrong interpretation, corresponding to (A) tuberculosis (TB)–positive subjects and (B) TB-negative subjects. Blue outlines encircle salient regions via Grad-CAM (35) that most influence the positive prediction from the DLS and are shown when the DLS considered the image positive. Yellow outlines were annotated by a radiologist to indicate regions of interest; solid outlines indicate findings consistent with TB while dotted outlines indicate other findings. “Confident” indicates that the DLS predicted values close to 0 or 1, whereas “challenging” indicates that the DLS predicted values close to the operating point (0.45). rads = Radiologists. Credit: Radiological Society of North America

"We wanted to see if this system predicts TB on par with radiologists, and that's what the study is showing," Pilgrim said. "AI performed really well with a variety of patients."

Trends were similar across different patient subgroups, including a test set from gold miners in South Africa, a group with a high prevalence of TB, compared to the general public.

"What's especially promising in this study is that we looked at a range of different datasets that reflected the breadth of TB presentation, different equipment and different clinical workflows," Kazemzadeh said. "We found that this deep-learning system performs really well with all of them with a single operating point that was pre-selected based on a development dataset, something that other medical imaging AI systems have found challenging."

If additional research supports the results, the deep-learning system could be used to automatically screen chest X-ray results for TB. People who test positive would then receive a sputum test or nucleic acid amplification testing (NAAT). These tests are relatively expensive, but if AI could filter the patients who need the test, the benefits would be

extensive. Simulations using the deep-learning system to identify likely TB positive chest X-rays for NAAT confirmation reduced the cost by 40% to 80% per positive TB patient detected.

"By screening patients in the community and detecting TB before they get really sick, they could have better outcomes and may require a shorter course of treatment," Pilgrim said. "Also, since TB is an infectious disease, if you can get to people early there will be less spread, compounding the benefits of this screening."

The researchers are conducting work in Zambia in a prospective setting, meaning they are collecting data from patients attending screening, and providing NAAT for every patient for the purpose of studying the system. They also are looking at ways to get these models out to the world in a way that can have the maximum impact for patients.

"We hope this can be a tool used by non-expert physicians and healthcare workers to screen people en masse and get them to treatment where required without getting specialist doctors, who are in short supply," Pilgrim said. "We believe we can do this with the people on the ground in a low-cost, high-volume way."

More information: Sahar Kazemzadeh et al, Deep Learning Detection of Active Pulmonary Tuberculosis at Chest Radiography Matched the Clinical Performance of Radiologists, *Radiology* (2022). [DOI: 10.1148/radiol.212213](https://doi.org/10.1148/radiol.212213)

Provided by Radiological Society of North America

Citation: AI-based system shows promise in tuberculosis detection (2022, September 13) retrieved 1 February 2024 from

<https://medicalxpress.com/news/2022-09-ai-based-tuberculosis.html>

This document is subject to copyright. Apart from any fair dealing for the purpose of private study or research, no part may be reproduced without the written permission. The content is provided for information purposes only.