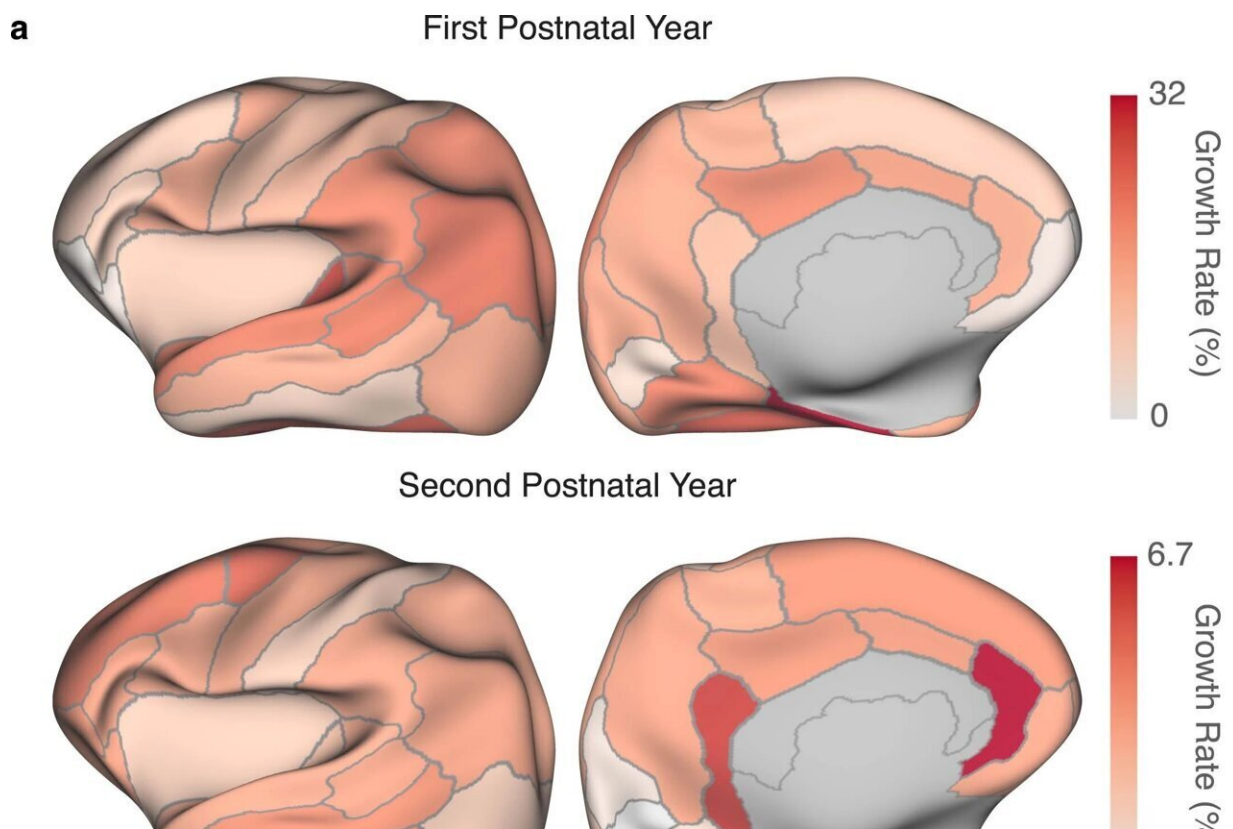


Researchers unveil new collection of human brain atlases that chart postnatal development

January 26 2023



Analysis of cortical thickness. a, Regional growth rates in terms of cortical thickness for the first (top row) and second (bottom row) postnatal years. b, ROI-specific mean laterality index for cortical thickness. Credit: *Nature Methods* (2022). DOI: 10.1038/s41592-022-01703-z

Human brain atlases can be used by medical professionals to track normative trends over time and to pinpoint crucial aspects of early brain development.

With these atlases, they are able to see what typical structural and functional development looks like, making it easier for them to spot the symptoms of abnormal development, such as attention-deficit/[hyperactivity disorder](#) (ADHD), dyslexia, and cerebral palsy.

Pew-Thian Yap, Ph.D., professor in the UNC Department of Radiology, and colleagues in the department and the Biomedical Research Imaging Center (BRIC) have created a new collection of month-by-month infant brain atlas (IBA) that capture fine spatiotemporal details of the early developing brain.

In this work, published in the journal *Nature Methods*, the scientists created a set of month-specific surface-volume longitudinal brain atlases of infants from 2 weeks to 2 years of age. Sahar Ahmad, Ph.D., research instructor of radiology, was lead author on the paper.

"Brain atlases are key to understanding neurodevelopment through the lenses of cellular composition, neural pathways, and functional organization," Yap said. "The human brain atlases created by our team depict the early development phase of postnatal neurodevelopment. Our atlases will be a resource valuable to brain scientists in unraveling key normative and aberrant traits of, arguably, the most important phase of human brain development."

Throughout the first two years of life, the [human brain](#) undergoes a whole range of cellular processes that drive the rapid growth of the infant brain. It is during this period that the brain changes structurally and reorganizes its neural circuits. When [development](#) goes awry, it can

have detrimental effects on the quality of life, including heightened risk for autism, schizophrenia, and ADHD.

By using the IBA, researchers are able to capture changes in [brain structure](#), cortical geometry, and tissue contrast.

The atlases also revealed that cortices in the temporal, parietal, and prefrontal regions of the brain are thicker than the primary visual and sensorimotor cortices. This is consistent with the finding that the higher-order functions of the infant brain—such as attention, working memory, inhibition, and problem-solving—mature more slowly than the areas of the [brain](#) that are responsible for the visual, motor, and sensory functions.

Overall, the surface-volume consistent IBA accurately captures the infant growth trajectories and does so with rich anatomical details. These atlases recorded the monthly changes in the normally developing brains' size, shape, and cortical geometry as well as their tissue contrast, volume, and microstructural characteristics from 2 weeks to 2 years of age.

"We hope that these atlases will become a common coordinate framework to facilitate the discovery of new insights into developmental processes underpinning child cognition and social behavior," Yap said.

More information: Sahar Ahmad et al, Multifaceted atlases of the human brain in its infancy, *Nature Methods* (2022). [DOI: 10.1038/s41592-022-01703-z](https://doi.org/10.1038/s41592-022-01703-z)

Provided by University of North Carolina School of Medicine

Citation: Researchers unveil new collection of human brain atlases that chart postnatal

development (2023, January 26) retrieved 10 July 2023 from
<https://medicalxpress.com/news/2023-01-unveil-human-brain-atlases-postnatal.html>

This document is subject to copyright. Apart from any fair dealing for the purpose of private study or research, no part may be reproduced without the written permission. The content is provided for information purposes only.