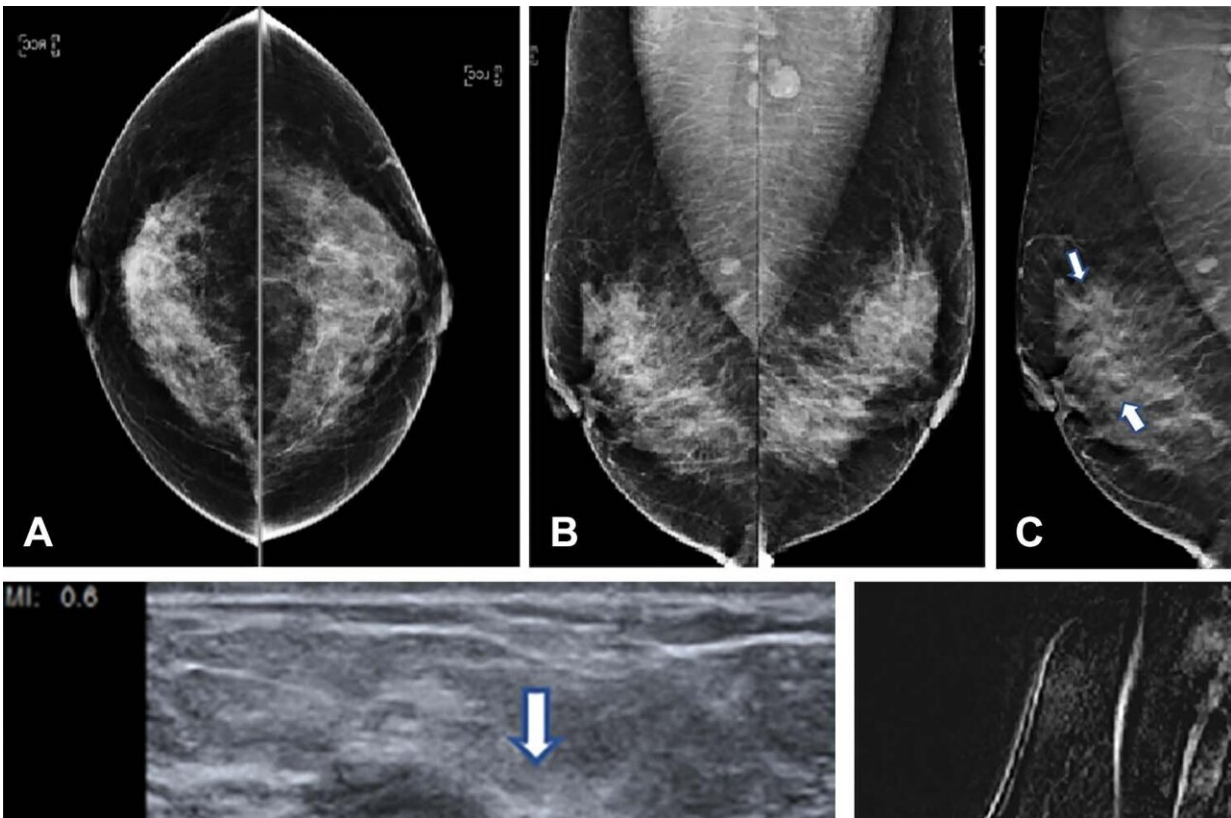


Huge study finds tomosynthesis better at breast cancer detection

March 14 2023



Images from a 42-year-old woman who presented for routine screening. (A) Two-dimensional craniocaudal digital mammogram and (B) two-dimensional mediolateral digital mammogram show heterogeneously dense breast tissue with no abnormality. (C) Mediolateral digital breast tomosynthesis image shows subtle architectural distortion (arrows) extending superiorly from the nipple level. (D) Target US image of the right breast shows a highly suspicious, hypoechoic, irregular mass (arrow). US-guided core biopsy yielded invasive ductal carcinoma with extensive ductal carcinoma in situ (T2N0M0; estrogen receptor–positive,

progesterone receptor–positive, and human epidermal growth factor receptor 2–negative). (E) Right-breast MRI scan acquired to evaluate the extent of disease shows a clip artifact in the superior aspect of the irregular enhancing mass (arrows). No other suspicious lesions were seen. Credit: Radiological Society of North America

In a study of over a million women, digital breast tomosynthesis (DBT) showed improved breast cancer screening outcomes over screening with standard digital mammography alone. The results of the study were published in *Radiology*.

Breast cancer is the most common cancer among women in the United States. While breast cancer mortality has been on the decline since the late 1980s due to improvements in early detection and treatment, it still remains the leading cause of cancer death among women.

The five-year relative survival rate of breast cancer when it is detected early in its localized stage is 99%, according to the American Cancer Society. Regular [screening](#) is the most reliable method for the early detection of breast cancer.

Screening with two-dimensional (2-D) [digital mammography](#) alone is still the standard of care at many sites, but it has its limitations due to its inability to detect some cancers. There is a growing amount of evidence that DBT, a more advanced technology, has a higher breast cancer detection rate due to its ability to capture multiple X-ray images of the breast from different angles rather than the typical single image obtained with a standard 2-D mammogram. DBT is especially beneficial for women with denser breast tissue.

"The purpose of our study was to evaluate screening outcomes among a

large cohort of women in the United States who were screened with either 2-D digital [mammography](#) alone or with DBT," said study co-author Emily F. Conant, M.D., FSBI, professor of radiology and chief in the Division of Breast Imaging at the Hospital at the University of Pennsylvania in Philadelphia.

For this [retrospective cohort study](#), Dr. Conant and colleagues compiled data from five large health care systems across the United States. The [study group](#) consisted of over 1 million women aged 40 to 79 who were screened with either DBT or 2-D digital mammography alone between January 2014 and December 2020. The screening outcomes such as cancer detection and false positive rates were compared across the two screening groups.

"This study was extremely large with most women having at least 2 screens resulting in over 2 million screening exams across five large and diverse health care systems," Dr. Conant said.

Compared to 2-D digital mammography alone, DBT was associated with important improvements in screening outcomes. The cancer detection rate for patients screened with DBT was higher at 5.3 per 1,000 screened, compared to 4.5 per 1,000 screened with 2-D digital mammography only. DBT also had a lower rate of false positives and recalls from screening.

"We showed that the most important mammographic screening outcomes, increased cancer detection combined with fewer false positives, were significantly improved when women were screened with [digital breast tomosynthesis](#) compared to 2-D digital mammography alone," Dr. Conant said. "Therefore, women should seek out sites that routinely offer [breast cancer](#) screening with DBT."

More information: Nila Alsheik et al, Mammographic Screening in

Routine Practice: Multisite Study of Digital Breast Tomosynthesis and Digital Mammography Screenings, *Radiology* (2023). DOI: [10.1148/radiol.221571](https://doi.org/10.1148/radiol.221571) pubs.rsna.org/doi/10.1148/radiol.221571

Provided by Radiological Society of North America

Citation: Huge study finds tomosynthesis better at breast cancer detection (2023, March 14) retrieved 19 March 2023 from <https://medicalxpress.com/news/2023-03-huge-tomosynthesis-breast-cancer.html>

This document is subject to copyright. Apart from any fair dealing for the purpose of private study or research, no part may be reproduced without the written permission. The content is provided for information purposes only.