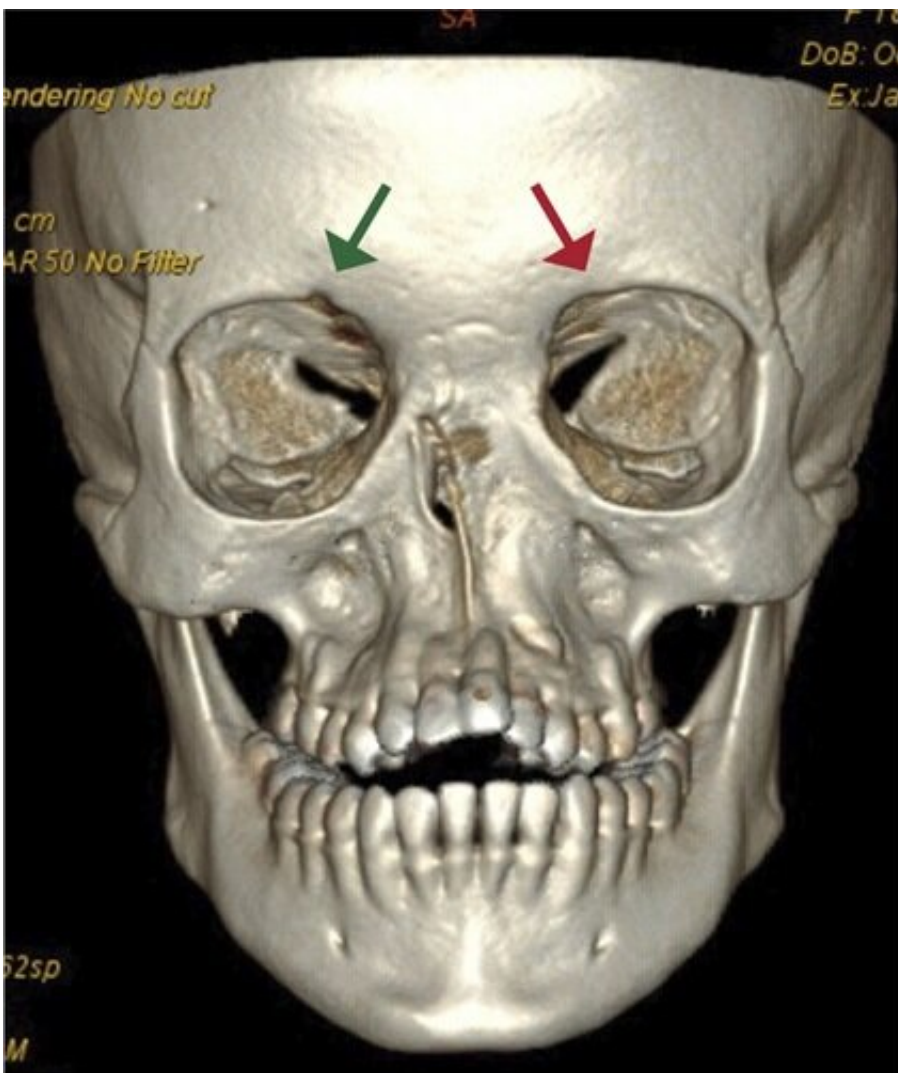


Innovative surgical technique creates a nose for patients with 'extremely rare' genetic syndrome

March 23 2023



Preoperative CT image of patient I showing the supratrochlear foramen present on the right (green arrow) and absent on the left side (red arrow). CT indicates

computed tomography. Credit: *Journal of Craniofacial Surgery* (2023). DOI: 10.1097/SCS.00000000000009261

Congenital arhinia (meaning patients born without a nose) is a rare condition associated with high mortality if not identified. As most babies when born are obligate nose breathers, the condition requires immediate attention. The clinical condition is a very rare genetic disorder that, in severe cases, causes congenital absence of the nose with life threatening conditions.

In a new report in *The Journal of Craniofacial Surgery*, an expert team of plastic and cranio-maxillofacial surgeons describes an innovative new approach to constructing a nose in two [young patients](#) with arhinia. The journal is published in the Lippincott portfolio by Wolters Kluwer. The condition involves function and appearance.

Eric C. Liao, MD, Ph.D., of Massachusetts General Hospital/Harvard Medical School and colleagues report on two [patients](#) from a family affected by congenital arhinia, and the surgical technique designed to create a cosmetically acceptable nose. The experience "highlights key principles of a staged approach to nasal construction in arhinia and discusses nuances and improvements learned between both patients," the researchers write.

Newly recognized mutation leads to congenital arhinia

"Arhinia is an extremely rare congenital condition with fewer than 100 cases reported in the literature worldwide," according to the authors. Only a few reports have described approaches to nasal construction in patients with complete arhinia—the condition is so rare that the operation is usually designed on a case-by-case basis.

Congenital arhinia is caused by mutations of a gene called SMCHD1. In the two new patients, modern genetic testing techniques identified a previously unknown SMCHD1 mutation. Congenital arhinia may take different forms: the mother of one of the patients had no sense of smell (anosmia), and another affected family member died. Even though it includes just two patients, the new article "is the largest pedigree of such cases in the literature."

Not only was the external nose absent, but the skeletal foundation of the midface was severely underdeveloped. The two patients had no facial air passages, so the newly created nose was nonfunctional; the patients were able to breathe through the mouth.

Staged technique enables successful construction of the nose

To meet the complex challenges posed by this severe defect, Dr. Liao and colleagues designed a staged approach to augment the underlying bones of the face and to construct an external nose. In the first stage, the patients underwent midface skeletal advancement using a standard technique (Le Fort II osteotomy), including placement of external distraction hardware to create new bone for use in reconstruction.

After a few months of healing, a tissue expander was placed under the skin of the forehead to create new soft tissue. In another few months, the new nose was created by placing this forehead tissue flap over a costochondral framework, crafted by surgeons using rib cartilage. Final steps consisted of further skin grafts to refine the appearance of the nasal tip. Experience in the first case enabled the surgeons to refine their approach in the second patient.

The procedure created "an esthetically pleasing shape of the external nose," improving the patients' facial appearance and lessening the social

impact of their deformity. The researchers write, "Both subjects recovered from the staged procedures without any postoperative complications and are pleased with their progress so far."

The approach developed in the new report "represents a unique and important opportunity to highlight key principles of nasal construction in arhinia," Dr. Liao and co-authors write. They add, "This guide offers an optimized guide to this surgical strategy for improved aesthetic and functional outcomes in these patients."

More information: Marie Bargiela et al, Nasal Construction in Congenital Arhinia Due to Novel SMCHD1 Gene Variant, *Journal of Craniofacial Surgery* (2023). [DOI: 10.1097/SCS.00000000000009261](https://doi.org/10.1097/SCS.00000000000009261)

Provided by Wolters Kluwer Health

Citation: Innovative surgical technique creates a nose for patients with 'extremely rare' genetic syndrome (2023, March 23) retrieved 13 May 2023 from <https://medicalxpress.com/news/2023-03-surgical-technique-nose-patients-extremely.html>

This document is subject to copyright. Apart from any fair dealing for the purpose of private study or research, no part may be reproduced without the written permission. The content is provided for information purposes only.