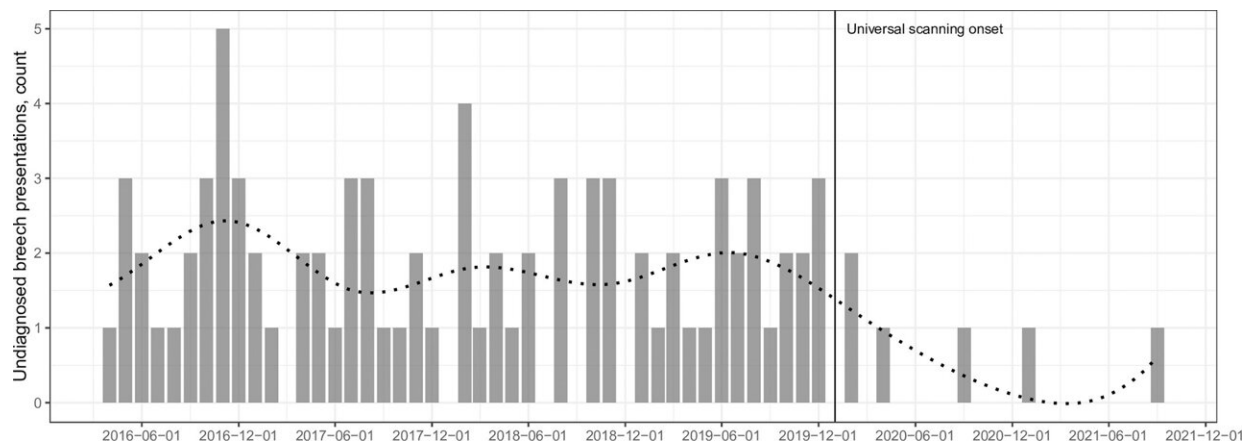


# Improved neonatal outcomes with routine third-trimester ultrasound in the UK

April 10 2023, by Justin Jackson



The number of term breech presentations that were undiagnosed during the study period in St. George’s University Hospital. Dotted line represents the fitted regression curve with splines. Credit: *PLOS Medicine* (2023). DOI: 10.1371/journal.pmed.1004192

A retrospective study using data from St. George's (SGH) and Norfolk and Norwich University Hospitals (NNUH) in the U.K. has examined the impact of routine third-trimester ultrasound on undiagnosed breech presentations.

In a paper published in *PLOS Medicine*, researchers led by Samantha Knights from the Department of Obstetrics and Gynecology, Norfolk and Norwich University Hospitals NHS Foundation Trust, and Smriti

Prasad of the Fetal Medicine Unit, St. George's University Hospitals NHS Foundation Trust, observed that a policy of routine third-trimester ultrasound was associated with a reduction in term breech presentations with an improvement in neonatal outcomes.

In an ideal birth, a baby's head is positioned downward (vertex position) and exits the vagina first. In the breech position, the baby's buttocks or feet are downward. Breech is common in early pregnancy, though most of these babies will turn on their own to a head-down position by week 36. The complications of breech position do not usually occur until it is time to deliver and can go unnoticed late into the third trimester. Breech position at delivery occurs in about 3% to 4% of full-term pregnancies, and is higher in pre-term.

Complications can be severe, with arms and legs out of position they can become dislocated or fractured. The [umbilical cord](#) can be poorly positioned, cutting off oxygen leading to potential nerve or brain damage. Breech vaginal birth is associated with an increase in both perinatal death and morbidity as well as maternal morbidity.

Correct knowledge of fetal position at term is essential for providing informed pregnancy and delivery care. Knowing ahead of time allows women to choose how to proceed. There can be an attempt to use physical manipulation (external cephalic version), a method that involves placing hands on the abdomen and applying firm pressure to turn the baby to a head-down position. Cesarean or vaginal birth can be selected, each with perceived risks and benefits.

The authors of the paper, "Impact of point-of-care ultrasound and routine third-trimester ultrasound on undiagnosed breech presentation and perinatal outcomes: An observational multicentre cohort study," point to substantial evidence that [clinical examination](#) is not accurate enough for determination of fetal presentation, with unacceptably high

rates of missed breech presentations at term.

The study looked at the before and after results of an implemented routine third-trimester ultrasound in two hospitals to gauge the effectiveness of the additional protocol. Women with multiple pregnancy, preterm (birth prior to 37 weeks), congenital abnormality, and those already undergoing planned [cesarean section](#) for breech presentation were excluded.

Before implementation, data sets were 16,777 births at SGH and 5,119 at NNUH, with 7,351 and 4,575, respectively, born after. The rate of breech presentation in labor was consistent in both groups (3% to 4%) and is the statistically expected rate. In the SGH cohort, the percentage of all term breech presentations that were undiagnosed was 14.2% (82/578) before and 2.8% (7/251) after the implementation of additional screening, a 71% reduction. In the NNUH cohort, the percentage of all term breech presentations that were undiagnosed was 16.2% (27/167) before and 3.5% (5/142) after the implementation, a 69% reduction.

The researchers conclude that both third-trimester [ultrasound](#) by sonographers or with a Point-of-Care Ultrasound (POCUS) used by trained midwives effectively reduced the number of undiagnosed breech presentations at delivery and resulted in fewer associated neonatal complications.

**More information:** Samantha Knights et al, Impact of point-of-care ultrasound and routine third trimester ultrasound on undiagnosed breech presentation and perinatal outcomes: An observational multicentre cohort study, *PLOS Medicine* (2023). [DOI: 10.1371/journal.pmed.1004192](#)

Citation: Improved neonatal outcomes with routine third-trimester ultrasound in the UK (2023, April 10) retrieved 20 April 2023 from <https://medicalxpress.com/news/2023-04-neonatal-outcomes-routine-third-trimester-ultrasound.html>

This document is subject to copyright. Apart from any fair dealing for the purpose of private study or research, no part may be reproduced without the written permission. The content is provided for information purposes only.