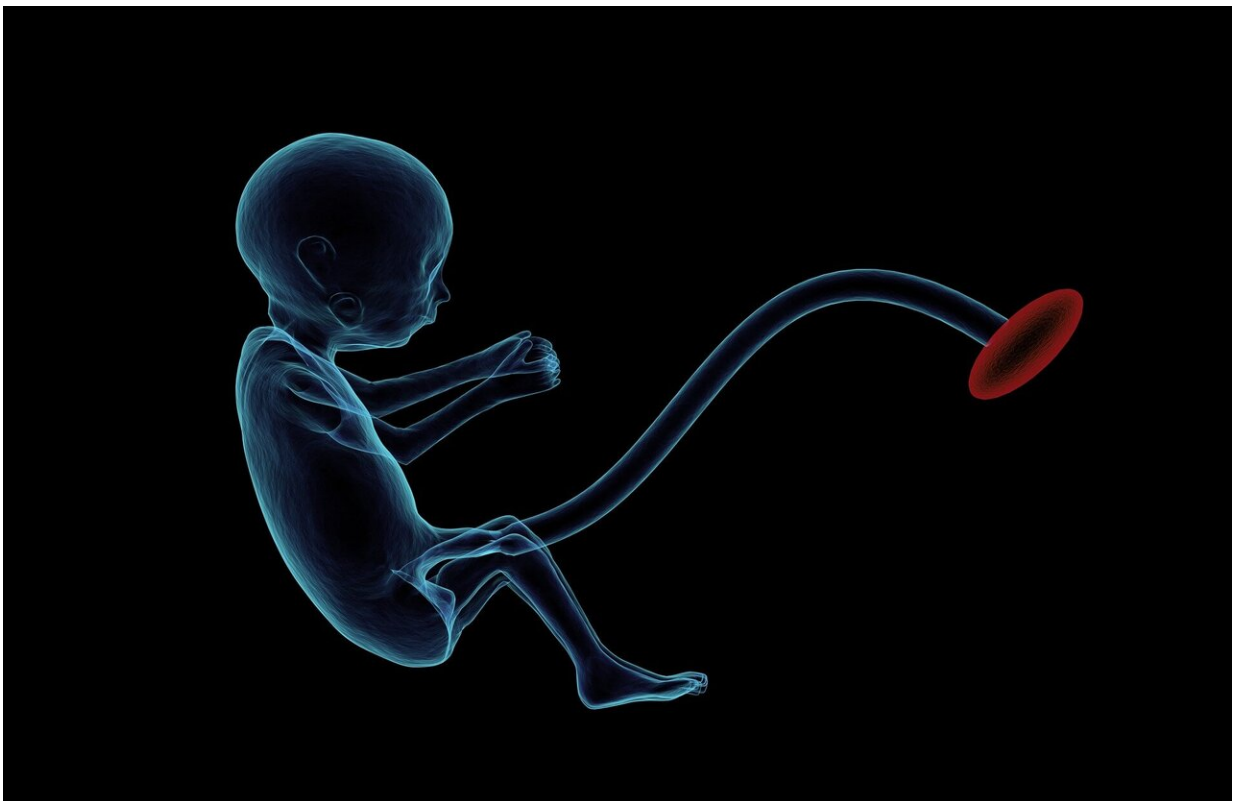


# Team performs first-of-its-kind, in-utero procedure to fix deadly vascular malformation

May 4 2023

---



Credit: Pixabay/CC0 Public Domain

In a first, a team from Brigham and Women's Hospital and Boston Children's Hospital successfully treated an aggressive vascular

malformation in an infant's brain before birth, avoiding potentially fatal symptoms after delivery.

Collaborating researchers and clinicians from Boston Children's Hospital and Brigham and Women's Hospital have prevented a deadly developmental condition by treating an aggressive vascular malformation in an infant's brain before birth. The case, which is the first-ever, in-utero cerebrovascular surgery in the United States, is described in a paper published today in *Stroke*.

As part of an ongoing clinical trial to treat vein of Galen malformation (VOGM) in utero, Boston Children's Hospital partnered with Brigham and Women's Hospital Fetal Therapy Program to perform the procedure in an obstetric operating room, with a maternal-fetal medicine specialist and fetal radiologist.

"In every fetal surgery, there are two patients: the baby and the mother, and caring for both the fetus and the mother is an important aspect of fetal procedures," said co-author Carol Benson, MD, staff radiologist at BWH and former co-director of BWH's High-Risk Obstetrical Ultrasound Service. "You need to make sure that everything is aligned perfectly, and we couldn't do anything without the precise communication and teamwork of everyone involved."

"In our trial, we are using ultrasound-guided transuterine embolization to address the vein of Galen malformation before birth, and in our first treated case, we were thrilled to see that the aggressive decline usually seen after birth simply did not appear. We are pleased to report that at six weeks, the infant is progressing remarkably well, on no medication, eating normally, gaining weight, and is back home. There are no signs of any negative effects on the brain," said lead study author Darren B. Orbach, M.D., Ph.D.

"While this is only our first treated patient and it is vital that we continue the trial to assess the safety and efficacy in other patients, this approach has the potential to mark a [paradigm shift](#) in managing vein of Galen malformation, where we repair the malformation prior to birth and head off the heart failure before it occurs rather than trying to reverse it after birth. This may markedly reduce the risk of long-term brain damage, disability, or death among these infants."

A team that included clinicians from radiology, neurointerventional radiology, anesthesiology and maternal fetal care performed the in-utero embolization on a fetus with vein of Galen malformation (VOGM) at 34 weeks and 2 days gestational age. The procedure was performed as part of a clinical trial performed with oversight from the U.S. Food and Drug Administration.

VOGM is a rare condition that occurs when misshapen arteries in the brain connect directly to veins instead of capillaries. This slows [blood flow](#) and can lead to high-pressure blood flowing into the veins. This increase in pressure can prevent an infant's brain from draining adequately and lead to widespread brain injury or severe loss of tissue in the brain. The standard of care is currently to treat infants with VOGM after they are born, but in many cases, brain damage has already occurred.

"Despite decades of refining the embolization-after-birth technique and the establishment of expert specialty referral centers around the world, fetuses that are diagnosed with vein of Galen malformation continue to have high mortality and high rates of severe neurological impairment," said Orbach. "Correcting the malformation before birth may prevent brain injury and the often-rapid decline seen after birth and may lead to better outcomes overall for these infants."

Because of the abnormally high blood flow in the [malformation](#), children

born with VOGM do not live long enough to have it diagnosed, with many of them dying within the first few days from heart failure. In this case, after in-utero treatment, the newborn did not require additional surgery after birth and [brain](#) MRI showed no strokes, fluid buildup, or hemorrhage often seen with VOGM. The baby, who was born in mid-March, was discharged after several weeks in the NICU and is hitting all of her milestones.

"The 20-year history of [fetal surgery](#) at the Brigham underscores the commitment to continuous improvement and collaboration between Boston Children's Hospital and Brigham and Women's Hospital," said co-author Louise Wilkins-Haug, MD, Division Director of Maternal-Fetal Medicine at Brigham and Women's Hospital. "This proof of concept was a highly collaborative effort between our two organizations for many years now, and to see it be so successful is really a testament to that mission."

**More information:** Darren B. Orbach et al, Transuterine Ultrasound-Guided Fetal Embolization of Vein of Galen Malformation, Eliminating Postnatal Pathophysiology, *Stroke* (2023). [DOI: 10.1161/STROKEAHA.123.043421](#)

Provided by Brigham and Women's Hospital

Citation: Team performs first-of-its-kind, in-utero procedure to fix deadly vascular malformation (2023, May 4) retrieved 20 July 2023 from <https://medicalxpress.com/news/2023-05-team-first-of-its-kind-in-utero-procedure-deadly.html>

<p>This document is subject to copyright. Apart from any fair dealing for the purpose of private study or research, no part may be reproduced without the written permission. The content is provided for information purposes only.</p>
--