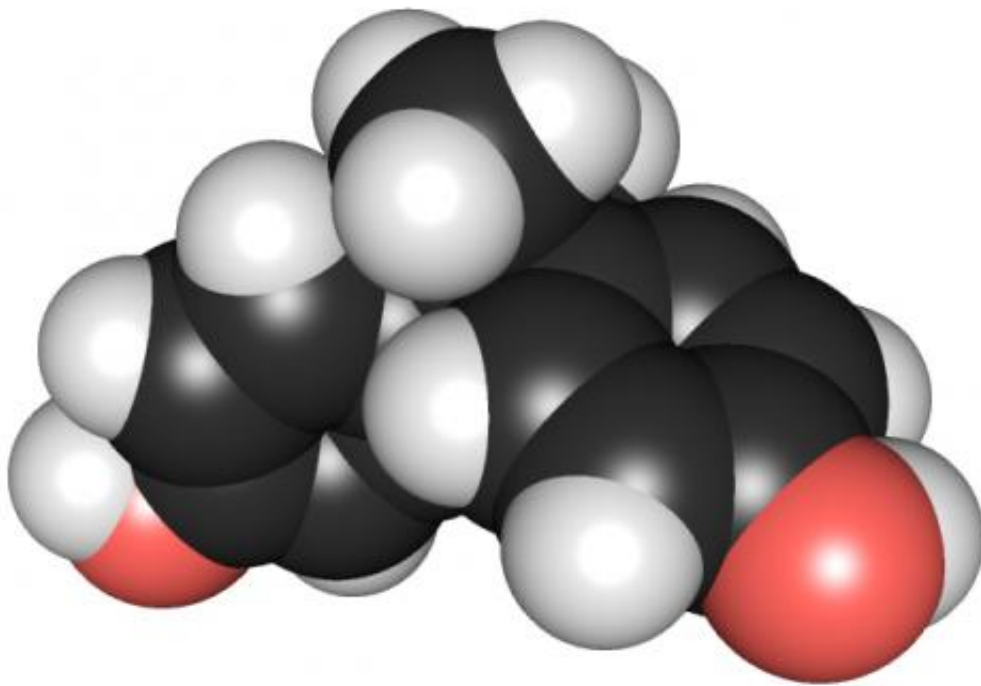


# BPA harms dental enamel in young animals, mimicking human tooth defect

March 6 2015

---



3D chemical structure of bisphenol A. Credit: Edgar181 via Wikimedia Commons

A tooth enamel abnormality in children, molar incisor hypomineralization (MIH), may result from exposure to the industrial chemical bisphenol A (BPA), authors of a new study conclude after finding similar damage to the dental enamel of rats that received BPA.

The study results will be presented Friday at the Endocrine Society's 97th annual meeting in San Diego.

"Human enamel defects may be used as an early marker of exposure to BPA and similar-acting endocrine disruptors," Babajko said.

BPA is an endocrine disruptor, or hormone-altering chemical, that has been linked to numerous adverse health effects in humans. It appears in many plastic and resin household products and food containers, including until recently baby bottles, sippy cups and infant formula packages.

Dental enamel is the hard covering protecting the teeth. MIH causes white or brown opaque spots on an affected child's permanent first molars and incisors (the middle four teeth on the top and bottom), which become sensitive, painful and prone to cavities. Recent published data show that MIH affects up to 18 percent of children ages 6 to 9 years. Although the cause is unclear, it appears to have an environmental origin, according to the study authors.

In the first part of the study, Sylvie Babajko, PhD, a researcher at the French National Institute of Health and Medical Research (INSERM) in Paris, and her colleagues gave rats low doses of BPA, comparable to exposure in humans. The rats received BPA from fetal life to 30 days after birth. She said BPA caused enamel defects similar to MIH in humans, especially in male rats.

In part 2 of the study, the investigators cultured and looked at rat ameloblast cells, which are present only during the formation of [tooth enamel](#), called amelogenesis. In humans, amelogenesis takes place from the third trimester of fetal development to 3 or 4 years after birth. This cell-based experiment showed that sex hormones target and influence dental epithelial cells.

"Our study shows, for the first time, that BPA affects dental cells, and subsequently enamel synthesis, using similar target molecules as those present in other organs," Babajko said.

She explained that these molecules are receptors for sex steroid hormones involved in organ development, endocrine homeostasis and hormone-sensitive cancers.

Babajko reported that an increase in estrogen activity had a greater effect on the tooth enamel in male rats than in female rats. This finding, she said, suggests possible sexual differences in [enamel](#) quality.

Provided by The Endocrine Society

Citation: BPA harms dental enamel in young animals, mimicking human tooth defect (2015, March 6) retrieved 3 April 2023 from <https://medicalxpress.com/news/2015-03-bpa-dental-enamel-young-animals.html>

This document is subject to copyright. Apart from any fair dealing for the purpose of private study or research, no part may be reproduced without the written permission. The content is provided for information purposes only.