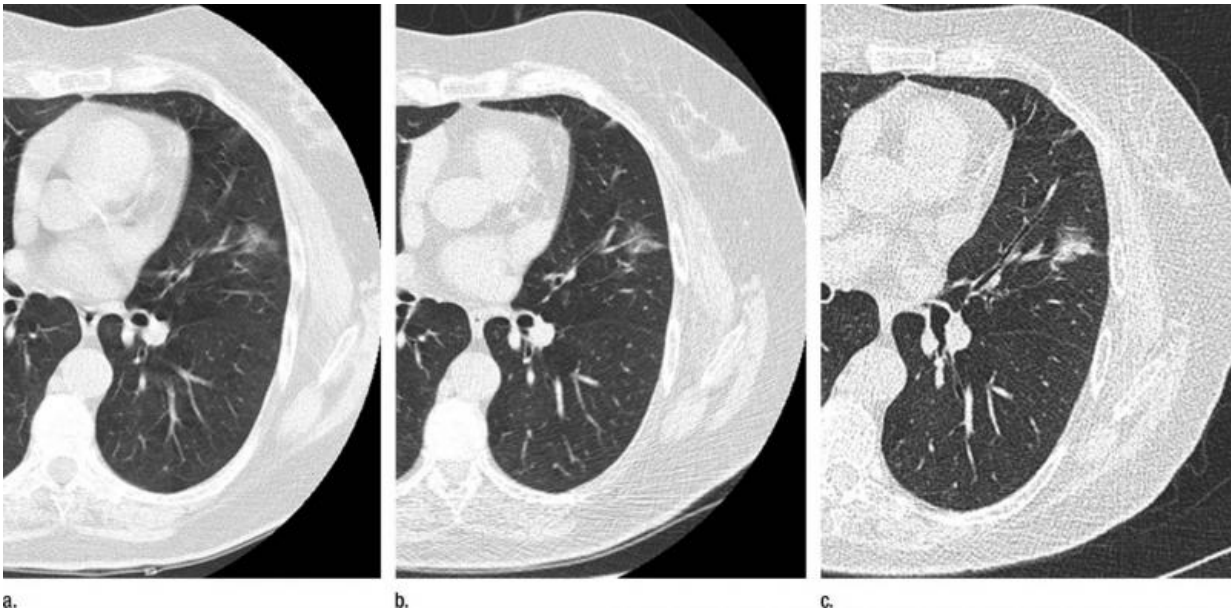


CT allows nonsurgical management of some lung nodules

June 23 2015



These CT images in a 68-year-old smoker show (a) a nonsolid nodule (17 3 13 mm) in the left upper lobe at baseline screening, (b) the nodule remained nonsolid at follow-up 2 years later, and (c) a solid component emerged at follow-up 9 years later. At that time, it was resected, and the final diagnosis was 2.1-cm invasive adenocarcinoma. Credit: Radiological Society of North America

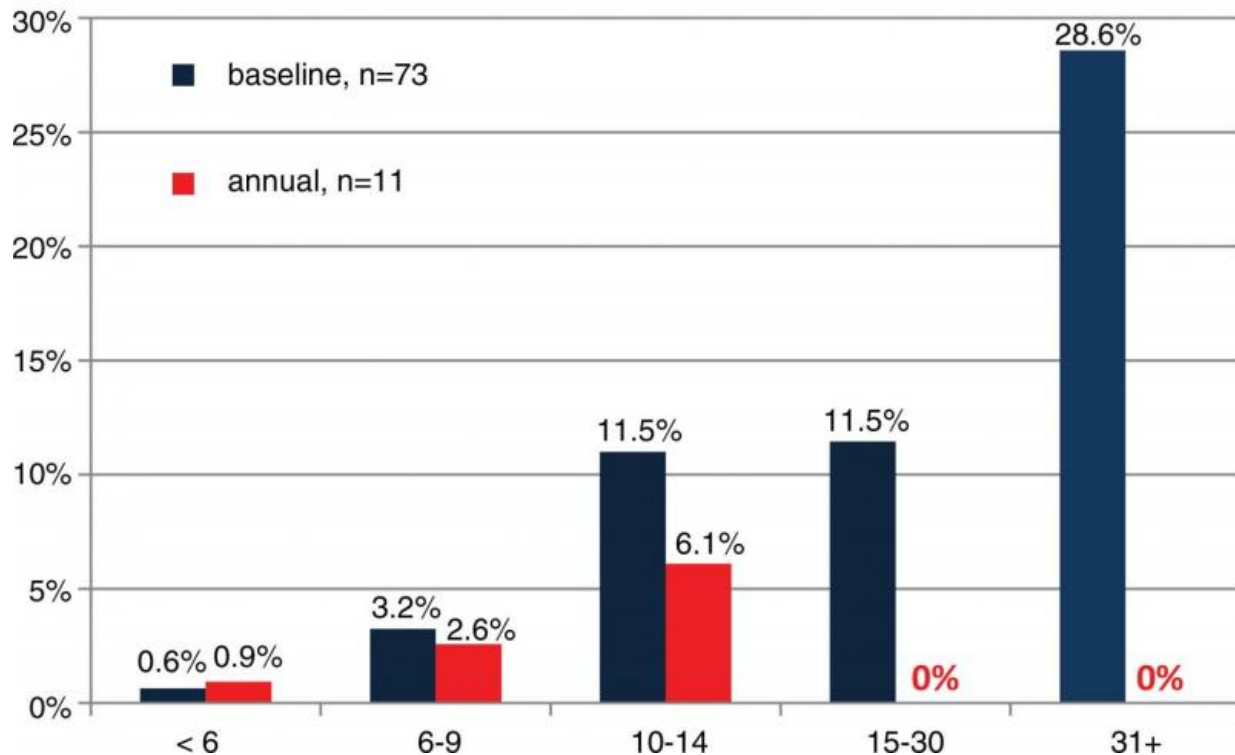
People who have nonsolid lung nodules can be safely monitored with annual low-dose computed tomography (CT) screening, according to a new study published online in the journal *Radiology*. Researchers said the findings could help spare patients from unnecessary surgery and

additional imaging.

Lung nodules are small masses of tissue in the lungs that can be benign or cancerous. They are classified as solid, part solid or nonsolid, based on their appearance on CT. In nonsolid [lung nodules](#), normal [lung](#) tissue is visible through the nodule. Nonsolid nodules are visible on CT scans of the chest, and management of them is challenging.

"Nonsolid nodules could be due to inflammation, infection or fibrosis, but could also be cancerous or a precursor of cancer," said study co-author Claudia I. Henschke, Ph.D., M.D., from the Department of Radiology at Mount Sinai School of Medicine in New York City. "For screening, we have to define which nodules need further workup and how quickly we have to do that workup."

In the new study, Dr. Henschke and colleagues analyzed results from 57,496 participants in the International Early Lung Cancer Program (I-ELCAP), a major worldwide initiative focused on reducing deaths from lung cancer. The patients underwent baseline and annual repeat screenings, and the researchers evaluated the prevalence of nonsolid nodules and their effect on long-term outcomes.



The likelihood of diagnosing a lung cancer manifesting in a nonsolid nodule, separately in the baseline (blue) and annual repeat (red) rounds of CT screening. Credit: Radiological Society of North America

A nonsolid nodule was identified in 2,392 (4.2 percent) of the baseline screenings, and further analysis led to the diagnosis of 73 cases of cancer. A new nonsolid nodule was identified in 485 of 64,677 annual repeat screenings, or 0.7 percent, and 11 were diagnosed with Stage I cancer. Surgery was 100 percent curative in all cases, with a median follow-up since diagnosis of more than six years.

The nonsolid nodule developed a solid component—a warning sign of invasive cancer—in 22 cases prior to treatment. However, the median transition time from nonsolid to part-solid was more than two years. No cancers occurred in new nodules 15 millimeters or larger in diameter.

The findings suggest that nonsolid nodules of any size can be safely followed with low-dose CT at 12-month intervals to assess a potential transition to part-solid.

"The results show that if we see a nonsolid lung nodule of any size, we can tell people to come back in one year for another CT," Dr. Henschke said. "These findings are important for reducing unnecessary CT scans and possible biopsies or surgery in programs of CT screening for lung cancer."

One immediate benefit may be a reduction in the overtreatment of nodules, according to study co-author David F. Yankelevitz, M.D., from Mount Sinai.

"Many recommendations had been fairly aggressive with respect to nonsolid nodules," Dr. Yankelevitz said. "These results show that there is no reason to be aggressive in pursuit of [cancer](#), so long as the nodules stay in this nonsolid form."

The study results also provide additional information to help in the shared decision-making process between physician and patient, Dr. Yankelevitz said. Patients can be assured that one-year low-dose CT screening intervals are sufficient, and also know that more aggressive treatment may be required if the nodules develop solid components.

"This is a major step forward for [lung cancer](#) screening protocols," Dr. Yankelevitz said. "It will help us cut down on the number of surgeries and unnecessary imaging tests."

More information: "CT Screening for Lung Cancer: Nonsolid Nodules in Baseline and Annual Repeat Rounds," *Radiology*, 2015.

Provided by Radiological Society of North America

Citation: CT allows nonsurgical management of some lung nodules (2015, June 23) retrieved 13 March 2023 from <https://medicalxpress.com/news/2015-06-ct-nonsurgical-lung-nodules.html>

This document is subject to copyright. Apart from any fair dealing for the purpose of private study or research, no part may be reproduced without the written permission. The content is provided for information purposes only.