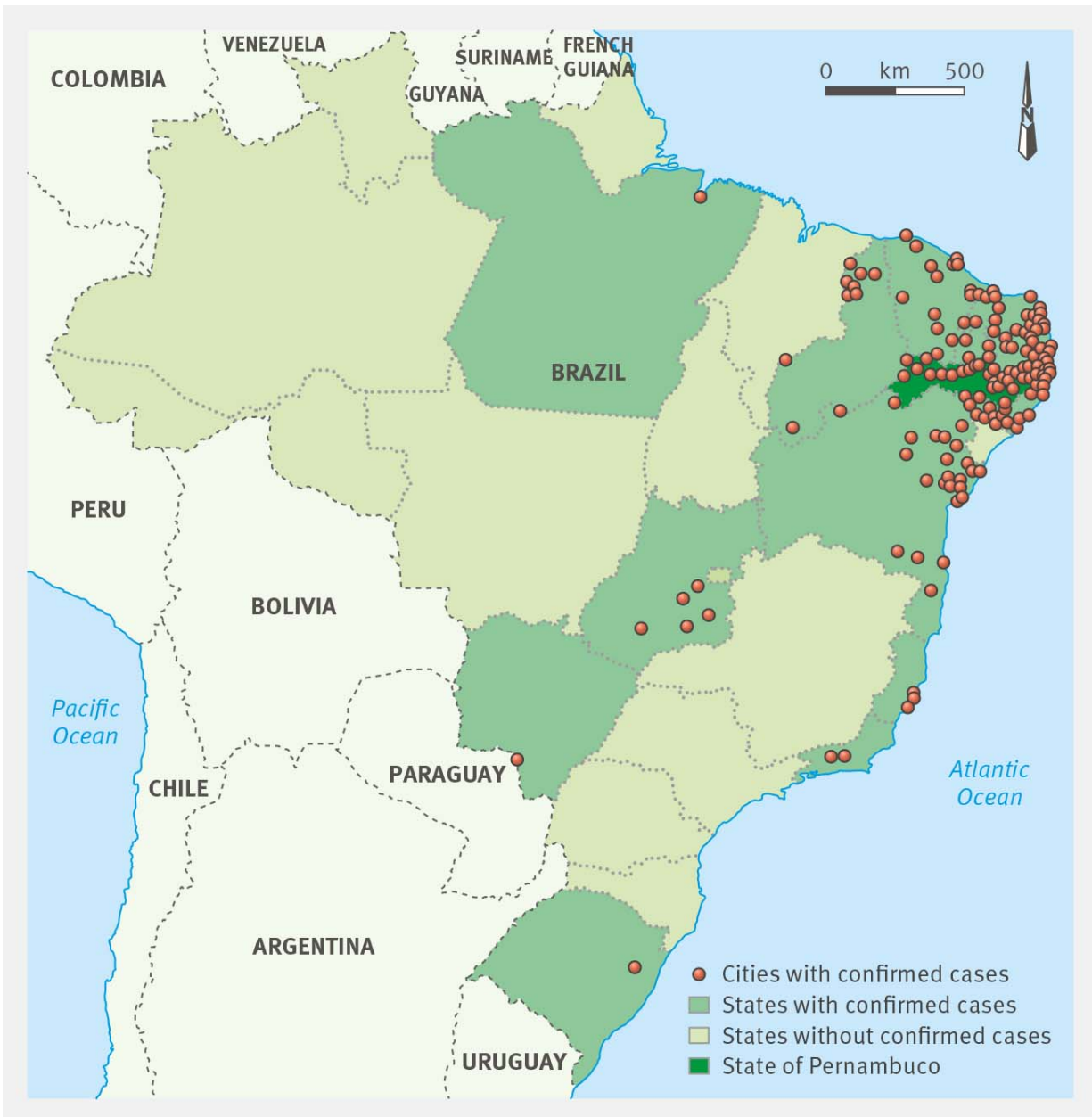

Scans confirm brain damage in babies born with microcephaly associated with Zika

April 13 2016



A map of Brazil showing cities with notified cases of microcephaly in Brazil up to Feb. 13, 2016. It's adapted from Brazilian Ministry of Health. Credit: BMJ 2016

Brain abnormalities in babies born with microcephaly and associated with the current Zika virus epidemic in Brazil are described by a team of doctors in a new study published in *The BMJ* today.

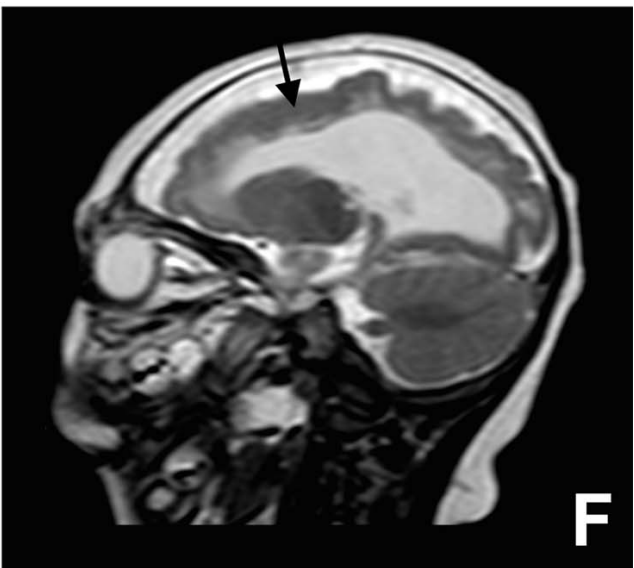
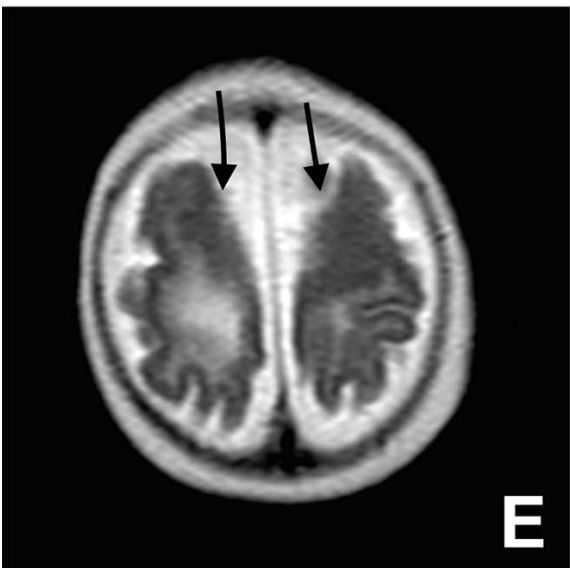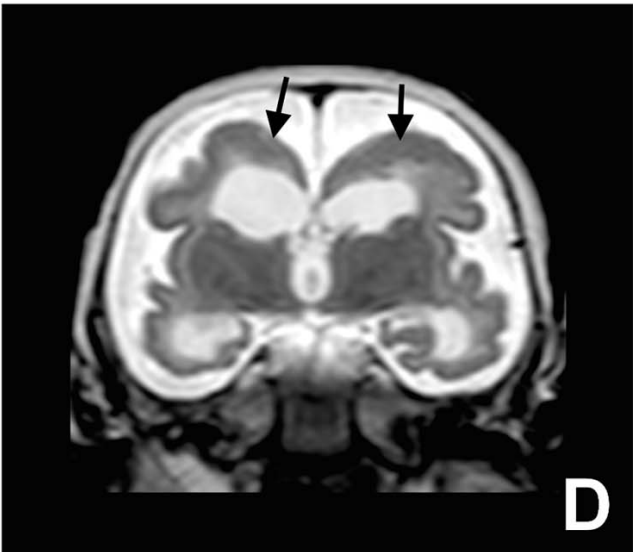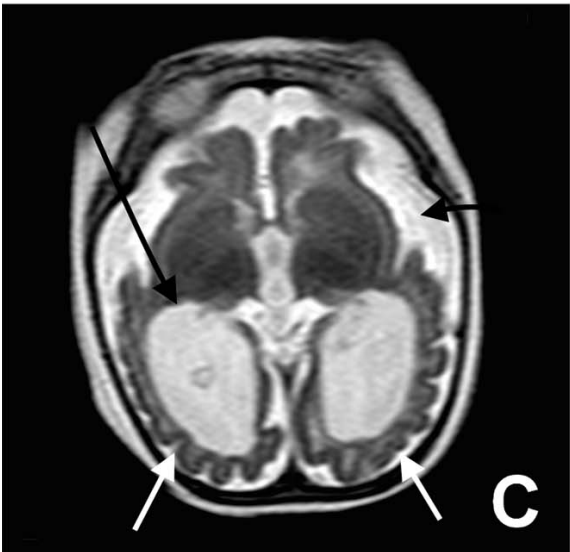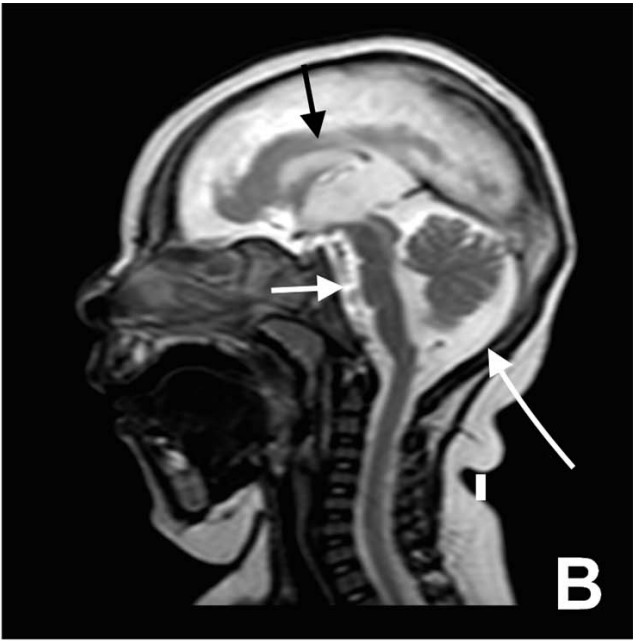
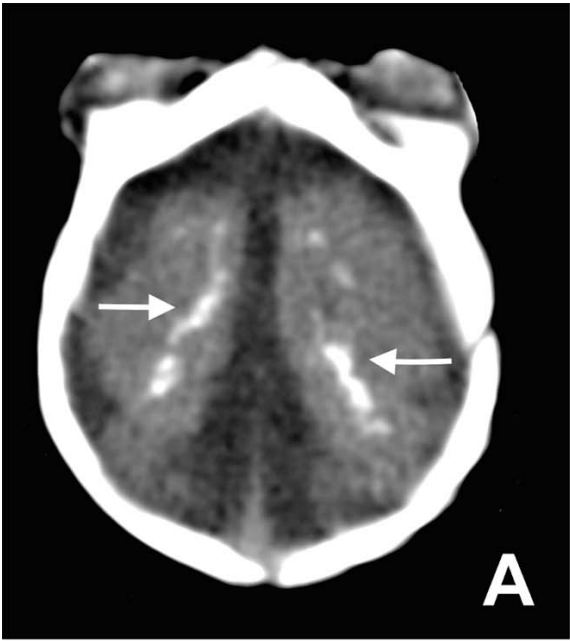
The findings show that [babies](#) born with microcephaly, presumably due to the Zika virus infection, have severe brain damage with a range of abnormalities.

"This study shows the largest and most detailed case series of neuroimaging findings in children with microcephaly and presumed Zika virus related infection to date," write the team of doctors from Recife, the Brazilian city at the centre of the global health crisis on Zika.

Microcephaly is a rare birth defect where a baby is born with an abnormally small head. Since 2015, Brazil has reported thousands of babies born with the condition, which has been linked to an increasing number of Zika virus infections.

In February 2016, the World Health Organization (WHO) declared the microcephaly epidemic an international public health emergency. Last month, it said there is strong scientific consensus that the Zika virus can cause microcephaly.

The team, led by Professor Maria de Fatima Vasco Aragao, analysed the types of abnormalities, and lesions in brain scans of the first cases of microcephaly associated with the Zika virus in Brazil.



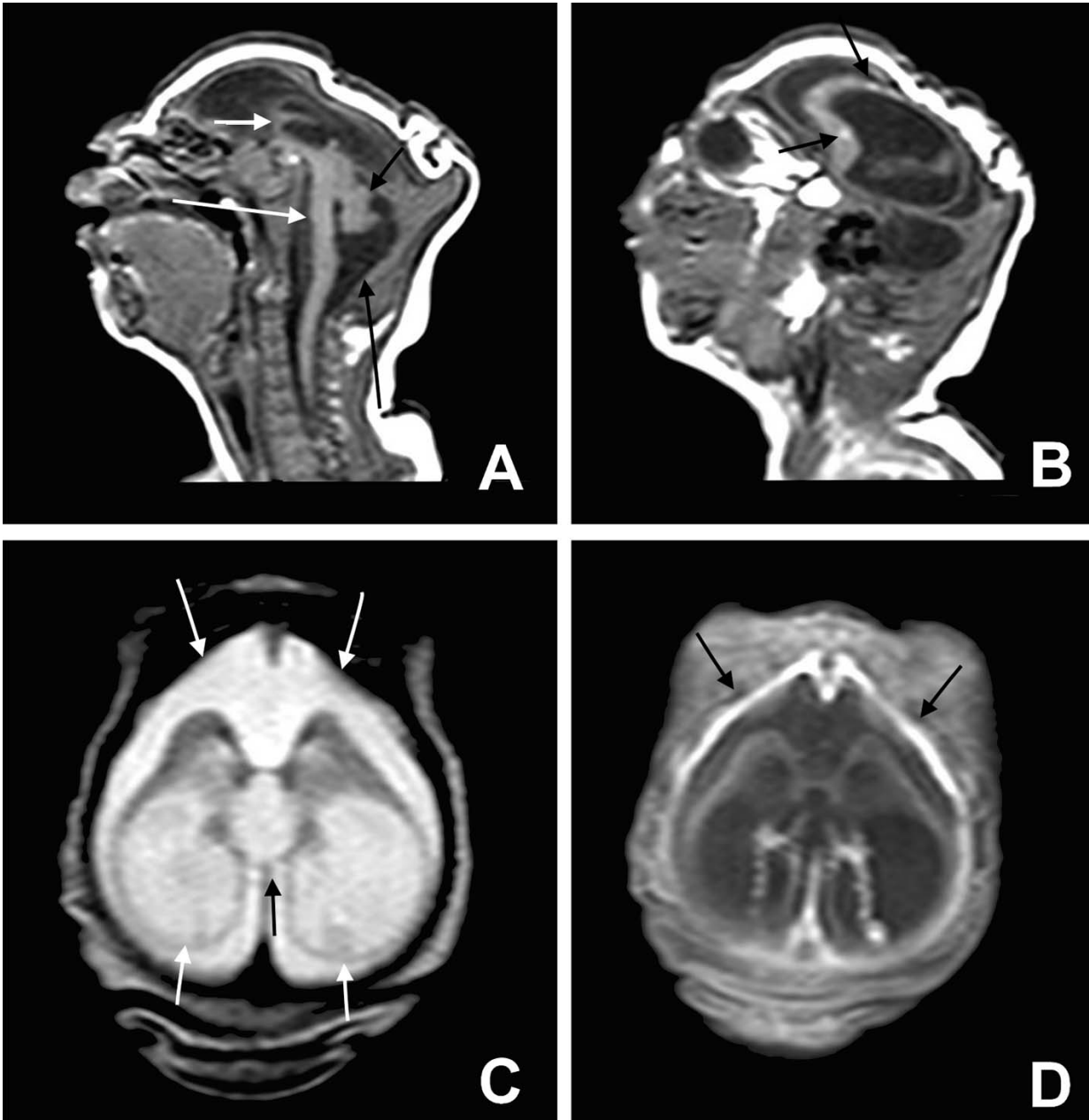
Microcephaly, cortical malformation, and brain calcification (see paper for more detailed description). Credit: BMJ 2016

It is the first time doctors have tried to distinguish the abnormalities in babies with microcephaly from the patterns seen with other congenital infections.

The analysis involved 23 babies diagnosed with a congenital infection associated with the Zika virus. Of these, 15 underwent a CT scan, seven underwent both CT and MRI scans, and one underwent MRI scan.

The babies were born in the Brazilian state of Pernambuco between July and December 2015. All, but one of the babies, were born to mothers who had a rash during pregnancy, consistent with a Zika virus infection.

Each baby was diagnosed with microcephaly or craniofacial disproportion during pregnancy or at birth. Six tested positive for antibodies related to the Zika virus, and the remaining 17 met the protocol criteria for microcephaly.



Severe microcephaly is shown (see paper for more detailed description). Credit: BMJ 2016

Other infectious causes of microcephaly were ruled out such as toxoplasmosis, cytomegalovirus, rubella, syphilis, and HIV.

The scans revealed that the majority of babies had brain damage that was "extremely severe, indicating a poor prognosis for neurological function," explain the doctors.

All babies who had a CT scan showed signs of brain calcification, a condition in which calcium builds up in the brain. The hypothesis is that the Zika virus destroys brain cells, and forms form lesions similar to "scars" on which calcium is deposited.

Other common findings included malformations of cortical development, decreased brain volume, and ventriculomegaly, a condition where the brain cavities are abnormally enlarged.

The doctors observed underdevelopment of the cerebellum, which plays an important role in motor control, and the brainstem which connects the cerebrum with the spinal cord and communicates messages from the brain to the rest of the body.

MRI scans showed that most babies had an enlarged cistern magna, probably due to reduced brain volume.

There was also delayed myelination, the process of a myeline sheath forming around nerve fibers that enables transmission of impulses, and abnormalities of the corpus callosum, the thick band of nerve fibers that connects and facilitates communication between the two hemispheres of the [brain](#).

This was an observational study so no definitive conclusions can be drawn about the effect of the Zika [virus](#) on these [brain abnormalities](#).

More information: Clinical features and neuroimaging (CT and MRI) findings in presumed Zika virus related congenital infection and microcephaly: retrospective case series study,

www.bmj.com/cgi/doi/10.1136/bmj.i1901

Provided by British Medical Journal

Citation: Scans confirm brain damage in babies born with microcephaly associated with Zika (2016, April 13) retrieved 14 March 2023 from <https://medicalxpress.com/news/2016-04-scans-brain-babies-born-microcephaly.html>

This document is subject to copyright. Apart from any fair dealing for the purpose of private study or research, no part may be reproduced without the written permission. The content is provided for information purposes only.