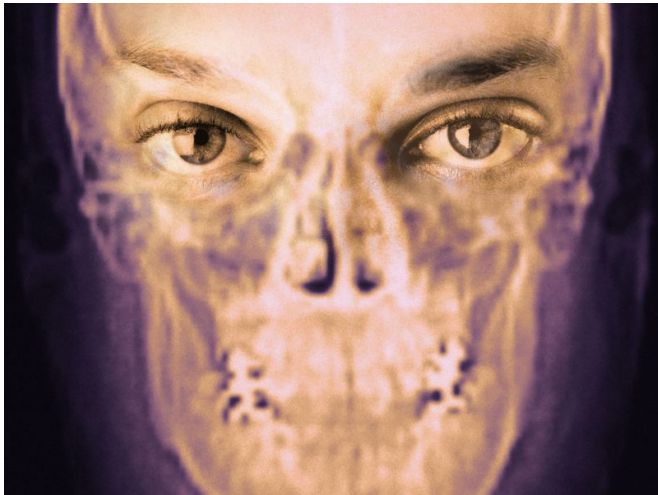


Nerve transposition technique successful in facial paralysis

25 June 2016



follow-up, three patients were excluded from functional analysis. In 16 of 17 patients there were improvements in facial symmetry at rest and during animation, with a median time for return of facial muscle tone of 7.3 months. At rest and with movement there was a significant reduction in facial asymmetry index. A significant increase in horizontal, vertical, overall lip excursion, and smile angle were detected on the MEEI FACE-gram software. None of the [patients](#) developed significant tongue atrophy, impaired tongue mobility, or dysfunction of speech or swallow.

"Mobilization of the intratemporal segment of the [facial nerve](#) provides adequate length for direct end-to-end coaptation to the hypoglossal nerve and is effective in restoring facial tone and symmetry after [facial paralysis](#)," the authors write.

More information: [Abstract](#)

[Full Text \(subscription or payment may be required\)](#)

(HealthDay)—After facial paralysis, mobilization and transposition of the intratemporal segment of the facial nerve for end-to-side coaptation to the hypoglossal nerve can restore facial tone and symmetry, according to research published online June 23 in *JAMA Facial Plastic Surgery*.

Amit Kochhar, M.D., from the University of California in Los Angeles, and colleagues conducted a case series involving patients with facial paralysis who underwent mobilization and transposition of the intratemporal segment of the facial nerve for end-to-side coaptation to the hypoglossal nerve. Twenty participants were treated at a tertiary care center between January 2007 and December 2014.

The researchers found that adequate length of facial nerve was mobilized for direct end-to-side coaptation to the hypoglossal nerve in all 20 patients. Prior to treatment, the median duration of facial paralysis was 11.4 months. Patients were followed for a median of 29 months; due to lack of

Copyright © 2016 [HealthDay](#). All rights reserved.

APA citation: Nerve transposition technique successful in facial paralysis (2016, June 25) retrieved 7 October 2022 from <https://medicalxpress.com/news/2016-06-nerve-transposition-technique-successful-facial.html>

This document is subject to copyright. Apart from any fair dealing for the purpose of private study or research, no part may be reproduced without the written permission. The content is provided for information purposes only.