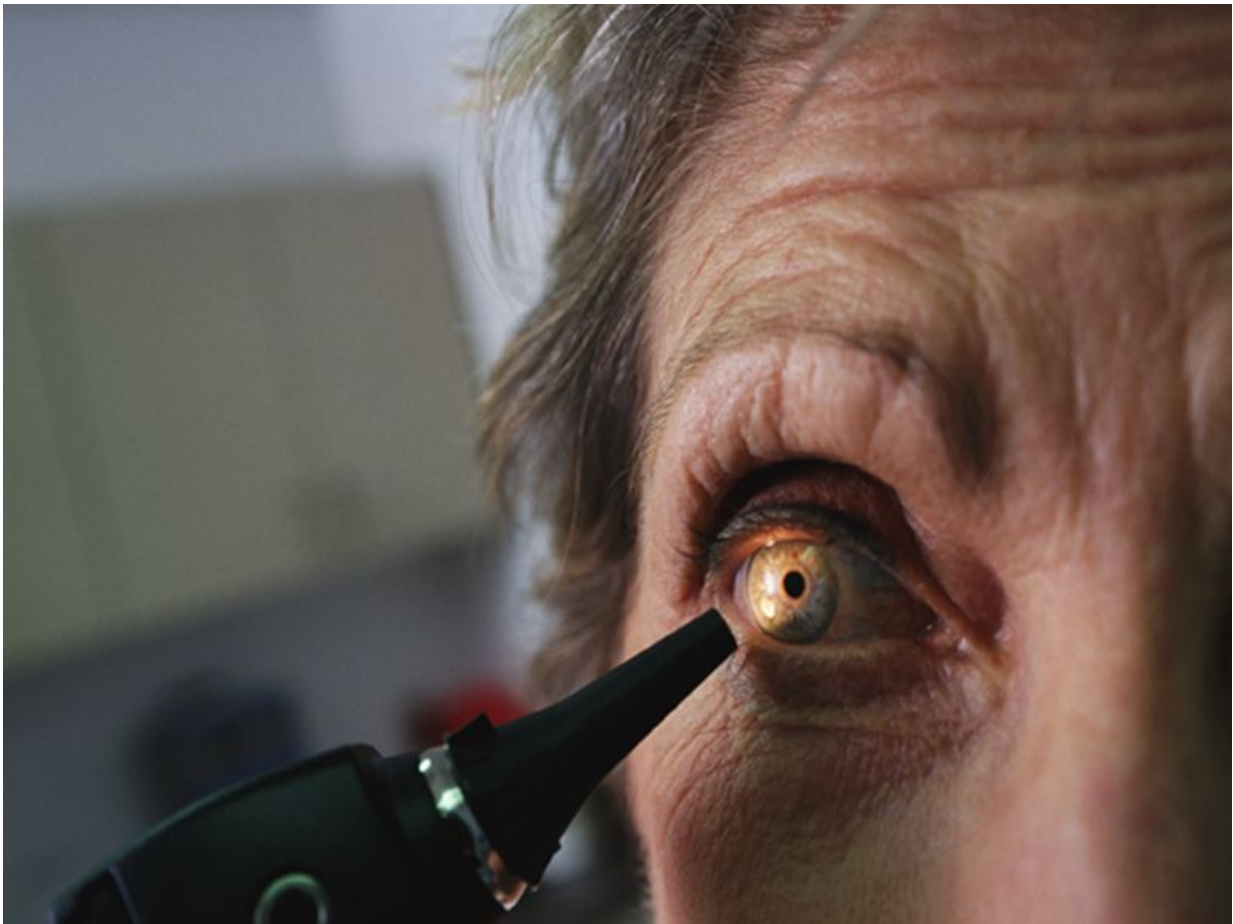


ECP, second drainage device effective in refractory glaucoma

September 1 2016



(HealthDay)—For patients with refractory glaucoma with failed initial

tube shunt, both endoscopic cyclophotocoagulation (ECP) and implantation of a second glaucoma drainage device (GDD-2) are effective as second surgeries, according to a study published online Aug. 28 in *Clinical & Experimental Ophthalmology*.

Yohko Murakami, M.D., from the University of California San Francisco, and colleagues conducted a nonrandomized retrospective chart review of [patients](#) with refractory glaucoma following a failed initial tube shunt. Patients underwent ECP (25 eyes) or GDD-2 with Baerveldt Glaucoma Implant (48 eyes) as a second surgery.

The researchers found that both ECP and GDD-2 correlated with significant reductions in intraocular pressure and number of antiglaucoma medications. At six and 12 months there were no significant differences in postoperative intraocular pressure or antiglaucoma medications between the groups. There were no between-group differences in survival outcomes.

"Both ECP and GDD-2 are both effective as second [surgeries](#) for refractory glaucoma that has failed a prior aqueous shunt," the authors write.

More information: [Abstract](#)
[Full Text \(subscription or payment may be required\)](#)

Copyright © 2016 [HealthDay](#). All rights reserved.

Citation: ECP, second drainage device effective in refractory glaucoma (2016, September 1) retrieved 4 February 2023 from <https://medicalxpress.com/news/2016-09-ecp-drainage-device-effective-refractory.html>

This document is subject to copyright. Apart from any fair dealing for the purpose of private

study or research, no part may be reproduced without the written permission. The content is provided for information purposes only.