

# Eczema drug restores hair growth in patient with longstanding alopecia

10 October 2018

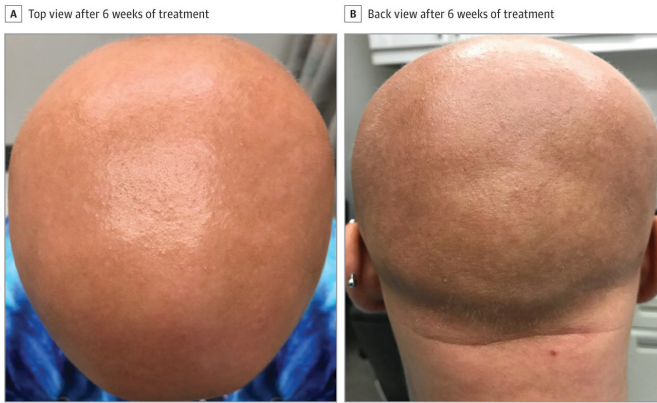


Image courtesy of JAMA Network®  
© 2018 American Medical Association

In addition to longstanding alopecia, this patient had experienced extensive, [treatment-resistant](#) eczema since the age of 7 months. Treatment with prednisone and methotrexate, medications that can suppress the overactive immune system, led to limited improvement in the patient's eczema but no [hair regrowth](#) and was therefore discontinued. In July 2017 she began to be treated with weekly injections of dupilumab, which had recently received FDA approval. After six weeks of treatment, which led to significant improvement in eczema symptoms, she also noticed that fine light hairs called vellus hairs were appearing on her scalp.

Fine light hairs called vellus hairs appear on the scalp of a patient with alopecia totalis six weeks after she began dupilumab treatment for eczema. Credit: *JAMA Network*.

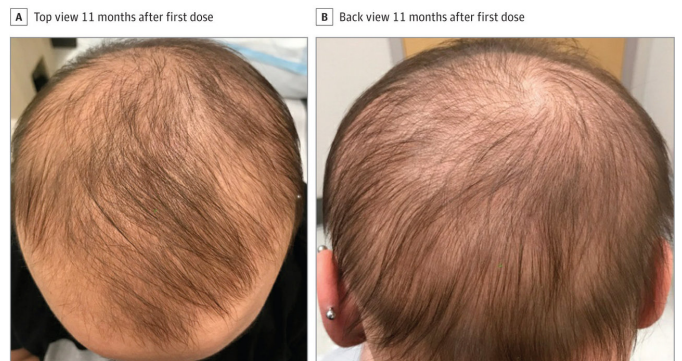

Image courtesy of JAMA Network®  
© 2018 American Medical Association

Massachusetts General Hospital (MGH) physicians are reporting an unexpected side-effect from treatment with dupilumab, which is FDA approved for the treatment of moderate to severe eczema, also called atopic dermatitis. In their case report published in *JAMA Dermatology*, the physicians describe how their 13-year-old patient, who has alopecia totalis—a total lack of scalp hair—along with eczema, experienced significant hair regrowth while being treated with dupilumab, a drug marketed under the brand name Dupixent.

After 11 months of dupilumab treatment, significant pigmented hair has grown across the patient's scalp. Credit: *JAMA Network*

"We were quite surprised since this patient hadn't grown scalp [hair](#) since the age of 2, and other treatments that can help with hair loss did not in her case," says Maryanne Makredes Senna, MD, of the MGH Department of Dermatology, senior author of the *JAMA Dermatology* report. "As far as we know, this is the first report of hair regrowth with dupilumab in a patient with any degree of alopecia areata."

After seven months of dupilumab treatment, the patient had grown a significant amount of the pigmented hair that typically grows on the scalp. Because of a change in her insurance coverage, she had to discontinue dupilumab for a two-month period, during which she noticed shedding of the recently regrown hair. But after she could resume treatment in April 2018, the hair growth resumed

and has continued.

Senna explains that dupilumab's mechanism of targeting a key immune system pathway known to be overactive in eczema could explain its action against alopecia, since recent studies have suggested other elements of the same pathway may induce autoimmune [hair loss](#). "Right now, it's hard to know whether dupilumab could induce hair growth in other alopecia [patients](#), but I suspect it may be helpful in patients with extensive active [eczema](#) and active [alopecia areata](#)," she says. "We've submitted a proposal for a clinical trial using dupilumab in this patient population and hope to be able to investigate it further in the near future." Senna is the principal investigator of the Hair Academic Innovative Research (HAIR) clinical research unit at MGH and an instructor in Dermatology at Harvard Medical School.

**More information:** *JAMA Dermatology* (2018).  
[DOI: 10.1001/jamadermatol.2018.29](https://doi.org/10.1001/jamadermatol.2018.29)

Provided by Massachusetts General Hospital

APA citation: Eczema drug restores hair growth in patient with longstanding alopecia (2018, October 10) retrieved 21 November 2022 from <https://medicalxpress.com/news/2018-10-eczema-drug-hair-growth-patient.html>

*This document is subject to copyright. Apart from any fair dealing for the purpose of private study or research, no part may be reproduced without the written permission. The content is provided for information purposes only.*