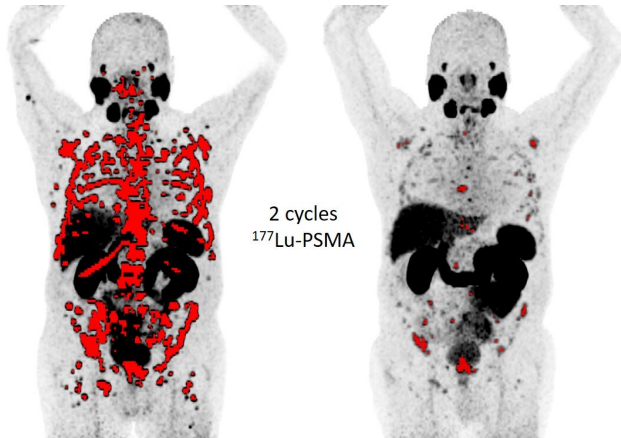


Interim scan during prostate cancer therapy helps guide treatment

24 June 2019



68Ga-PSMA11 PET MIP images at baseline and after 2 cycles of 177Lu-PSMA radioligand therapy in a patients with mCRPC. Credit: Andrei Gafita, Matthias Eiber, TUM School of Medicine, Klinikum rechts der Isar, Munich, Germany.

New prostate cancer research shows that adding an interim scan during therapy can help guide a patient's treatment. Prostate-specific membrane antigen (PSMA) positron emission tomography (PET) imaging of patients with metastatic castration-resistant prostate cancer after two cycles of lutetium-177 (177Lu)-PSMA radioligand therapy has shown a significant predictive value for patient survival. The research was presented at the 2019 Annual Meeting of the Society of Nuclear Medicine and Molecular Imaging (SNMMI).

According to the National Cancer Institute, currently the five-year survival rate for men with [metastatic prostate cancer](#) is 30.5 percent. Early assessment of treatment effectiveness is essential to providing optimal care.

In phase 2 trials, 177Lu-PSMA therapy has shown promising results in treating patients with metastatic castration-resistant prostate cancer.

The therapy typically involves a preliminary PSMA PET scan to identify patients who are eligible for the treatment. While interim PET scans have shown high predictive value for lymphoma patients, this concept has not been previously explored in prostate cancer patients undergoing 177Lu-PSMA therapy.

The [retrospective analysis](#) was conducted at Klinikum rechts der Isar hospital, Technical University Munich, Germany including patients who underwent gallium-68 (68Ga)-PSMA11 PET/CT at baseline and after two cycles of 177Lu-PSMA RLT under a compassionate use program.

Instead of standardized uptake value, which is the parameter generally used in such analyses, researchers used qPSMA, an in-house developed software, to evaluate the whole-body tumor burden. "Tumor response was assessed by the changes in PSMA-avid tumor volume from baseline to the second PSMA PET using three classification methods," explained Andrei Gafita, MD. "Subsequently, we found that tumor response assessed on interim PSMA PET after two RLT cycles was associated with overall survival."

Gafita stated, "Our results therefore show that interim PSMA PET can be used for therapeutic response assessment in patients undergoing 177Lu-PSMA RLT. Furthermore, occurrence of new lesions in PSMA PET is a prognostic factor for [disease progression](#) and could be included in defining [tumor response](#) based on PSMA PET imaging."

"While further analyses involving clinical parameters are warranted," Gafita adds, "this analysis paves the way for use of interim PSMA PET in a prospective setting during 177Lu-PSMA radioligand therapy."

More information: Abstract 73: "Predictive Value of Interim PSMA PET During 177Lu-PSMA

Radioligand Therapy for Overall Survival in Patients
with Advanced Prostate Cancer"

Provided by Society of Nuclear Medicine and
Molecular Imaging

APA citation: Interim scan during prostate cancer therapy helps guide treatment (2019, June 24)
retrieved 27 August 2022 from <https://medicalxpress.com/news/2019-06-interim-scan-prostate-cancer-therapy.html>

This document is subject to copyright. Apart from any fair dealing for the purpose of private study or research, no part may be reproduced without the written permission. The content is provided for information purposes only.