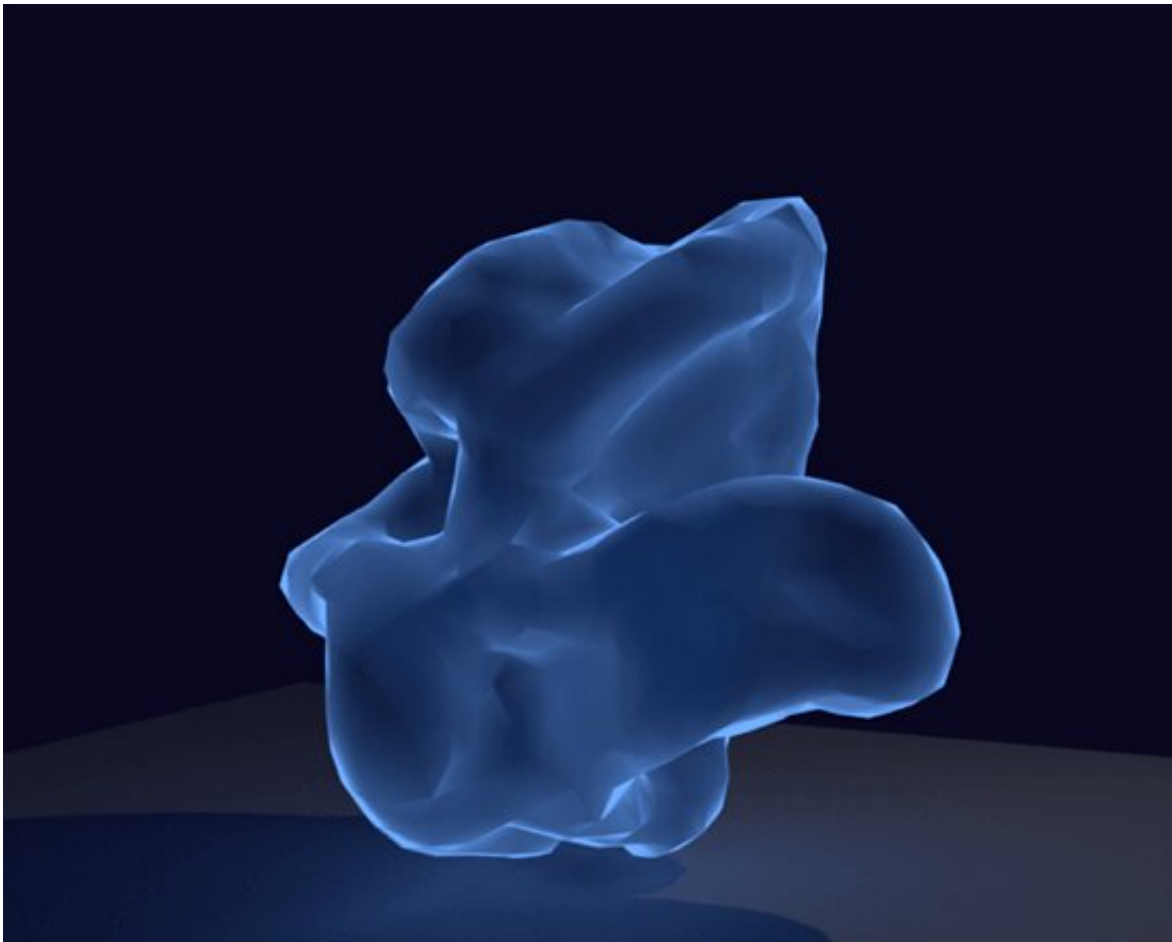


3-D brain imaging may improve treatment path for MS patients

July 15 2019, by Stephen Fontenot



This illustration shows an isolated MS lesion in 3-D. Credit: University of Texas at Dallas

A new way of looking at the brains of multiple sclerosis (MS) patients

could greatly enhance doctors' ability to select the best therapy for each person.

Researchers from The University of Texas at Dallas' Center for BrainHealth have joined colleagues at UT Southwestern Medical Center to study 3-D images of MS lesions in the brain, with the aim of learning to differentiate between injuries that are likely to heal and those that are not.

In a study published online May 30 in the Journal of Neuroimaging, the researchers examined 109 brain lesions from 23 MS patients using a patent-pending technique employing 3 Tesla MRI.

"Studying a lesion and the tissue surrounding it in three dimensions is a novel approach," said Dr. Dinesh Sivakolundu, the lead author of the study and a Ph.D. student in the Department of Biological Sciences at UT Dallas. "This has allowed us to compile a list of defining characteristics of MS lesions, including cerebral blood flow, metabolic rate of oxygen, and their shape and texture."

Understanding the significance of each detail and having reliable images of the area will improve the prospects of choosing the appropriate therapy for individual patients, Sivakolundu said.

"Right now, the state of the art for assessing MS lesions is getting multiple two-dimensional cross sections," said Sivakolundu, who holds a medical degree from Government Kilpauk Medical College in Chennai, India. "This leaves out data on the severity of the underlying injury, the harm done to the tissue surrounding those lesions and an estimate of how long the lesion has existed. There is very little data for determining if a lesion can heal or not."

Established pharmaceutical therapies for MS focus on using

immunosuppressive medication to limit further neurological damage. However, [new drugs](#) are expected to be available soon that enhance the capacity of an existing lesion to heal if it is able. This occurs through a process called remyelination—restoring the damaged myelin coverings of nerve cells to reestablish their ability to conduct the electrical signals that make the brain work.

Dr. Darin T. Okuda, senior author of the study, is a professor in the Department of Neurology and Neurotherapeutics at UT Southwestern and director of the Neuroinnovation Program. Members of his laboratory performed the 3-D phenotyping of [brain lesions](#) in collaboration with Dr. Xiaohu Guo, a professor of computer science in UT Dallas' Erik Jonsson School of Engineering and Computer Science.

"We're studying how the three-dimensional structure and surface characteristics of lesions impact the surrounding brain tissue," Okuda said. "Our findings are significant because they provide clarity on lesion age and the potential for myelin repair, which are not readily apparent with current MRI techniques. This new technique may serve as an ideal platform for the study of myelin repair treatments in the near future."

Dr. Bart Rypma, also a senior author of the study, said the current treatment-prescribing method leaves open the potential for patients to be on a drug long term even though it might not help them. This becomes particularly risky with drugs that suppress the immune system.

"Our approach will give more information to doctors in the clinic who have to make judgments about which therapeutic course to try," said Rypma, professor of psychology and the Meadows Foundation Chair in Behavioral and Brain Sciences at UT Dallas.

In the current study, researchers used 3 Tesla MRI to classify a lesion and its periphery in terms of several measurements. The results indicate

that approximately one-third of MS lesions show signs of a high probability of repair.

"If a lesion does not have the capacity to heal, remyelinating drugs aren't going to help," Sivakolundu said. "Our technique becomes a biomarker for targeted therapy because we can now decide if a lesion is likely to heal. From that, we can decide which drug regimen is worthwhile."

The best indicator of lesion-healing potential is what the team calls BOLD slope, where BOLD stands for "blood oxygen level dependent." It compares the amount of oxygen available at the injury site to that of its surroundings.

"When we compare a lesion to the tissue around it, we see either an increase or a decrease in the amount of oxygen present as you move outward from the center," Sivakolundu said. "That's the BOLD slope. If the amount of oxygen is higher in the peripheral area, that's a lesion that can be repaired. The surrounding tissue can supply blood and oxygen to enable healing."

Sivakolundu added that 3-D imaging conveys crucial information about how smooth or round a lesion is.

"Lesions that have the capacity to heal are more spherical in shape, with fewer jagged boundaries," he said. "They also have rougher surfaces, as opposed to smooth, because roughness indicates high metabolism in the surrounding cells."

Sivakolundu said that identifying newer lesions by their metabolic activity level also could indicate a more effective treatment plan for patients who need immunosuppressive medication.

"The current drugs are designed to prevent a relapse, which is more

likely in newer lesions," he said. "So patients with newer injuries might require more intense immunosuppressive therapy than those with less active lesions."

Rypma emphasized that their work, which is a segment of a large project on cognitive decline in MS patients, intends to equip clinicians with better data.

"We're helping doctors evaluate one therapeutic course against another," he said. "Either a patient's [lesions](#) can be healed, and they should choose the path of remyelination therapy, or they should choose the current therapy and focus on damage limitation."

More information: Dinesh K. Sivakolundu et al. Three-Dimensional Lesion Phenotyping and Physiologic Characterization Inform Remyelination Ability in Multiple Sclerosis, *Journal of Neuroimaging* (2019). [DOI: 10.1111/jon.12633](https://doi.org/10.1111/jon.12633)

Provided by University of Texas at Dallas

Citation: 3-D brain imaging may improve treatment path for MS patients (2019, July 15) retrieved 30 March 2023 from <https://medicalxpress.com/news/2019-07-d-brain-imaging-treatment-path.html>

<p>This document is subject to copyright. Apart from any fair dealing for the purpose of private study or research, no part may be reproduced without the written permission. The content is provided for information purposes only.</p>
--