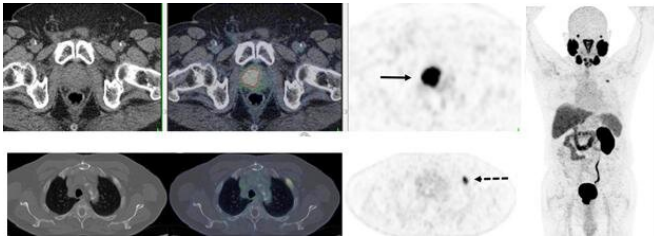


# In recurrent prostate cancer, PSMA PET/CT changes management in two-thirds of cases

13 July 2020



PSMA PET/CT accurately detects recurrent prostate cancer in 67-year-old man. 18F-DCFPyL-PSMA PET/CT shows extensive, intensely PSMA-avid local recurrence in prostate (bottom row; solid arrow) in keeping with the known tumor recurrence in the prostate. Right: PET shows extensive, intensely PSMA-avid local recurrence in prostate (top row; solid arrow) and a solitary bone metastasis in left rib 2 (bottom row; dotted arrow). Credit: Ur Metser, et al.

New research confirms the high impact of PSMA PET/CT in the detection and management of recurrent disease in prostate cancer patients. In initial results from a multicenter trial assessing the impact of 18F-DCFPyL prostate-specific membrane antigen positron emission tomography/computed tomography (PSMA PET/CT), a PET-directed change in management was observed in two-thirds of patients. The research was presented at the Society of Nuclear Medicine and Molecular Imaging's 2020 Virtual Annual Meeting.

Prostate [cancer](#) is the second most common cancer in men in the United States. According to the American Cancer Society, an estimated one in nine men will receive a prostate cancer diagnosis in his lifetime, and more than 191,000 men will be diagnosed with prostate cancer this year. Approximately 30 to 40 percent of men experience a biochemical recurrence of prostate cancer in which their [prostate-specific antigen](#) (PSA) levels rise after initial treatment.

DCFPyL (PSMA) PET/CT has been shown to be effective in diagnosing patients with prostate cancer. To assess its impact on the management of patients with suspected limited recurrent [prostate cancer](#) after primary therapy, researchers conducted a prospective, large-scale multicenter trial. The study included 410 men who had biochemical failure after primary therapy, had either no or limited disease on conventional imaging (CT and bone scintigraphy), and had undergone one of several [prostate cancer](#) treatments.

PSMA PET/CT identified disease in more than half of the men in whom CT and bone scan scintigraphy was negative. Additional sites of disease were observed in nearly two-thirds of patients in whom limited metastases were detected prior to PET. PSMA PET-directed management changes were recorded in 66 percent of the patients. The most common changes were conversion from observation or systemic therapy to surgery or radiation, or the addition of nodal-directed therapy to salvage surgery or radiation.

"The identification of extent of recurrence and specific sites of recurrence is crucial in determining the most appropriate mode of therapy for these men," noted Ur Metser, MD, professor of radiology at the University of Toronto in Ontario, Canada. "Findings from this study add to the body of evidence on the utility of PSMA PET in the management of [prostate cancer patients](#)."

He continued, "At this time, PSMA PET remains investigational in North American jurisdictions. Evidence generated from this study will help in seeking regulatory approvals to make molecular imaging with 18F-DCFPyL widely available and will pave the way for [clinical studies](#) that incorporate PSMA PET as a treatment planning tool to assess ultimate impact on patient outcomes."

Provided by Society of Nuclear Medicine and

## Molecular Imaging

APA citation: In recurrent prostate cancer, PSMA PET/CT changes management in two-thirds of cases (2020, July 13) retrieved 10 September 2022 from <https://medicalxpress.com/news/2020-07-recurrent-prostate-cancer-psma-petct.html>

*This document is subject to copyright. Apart from any fair dealing for the purpose of private study or research, no part may be reproduced without the written permission. The content is provided for information purposes only.*