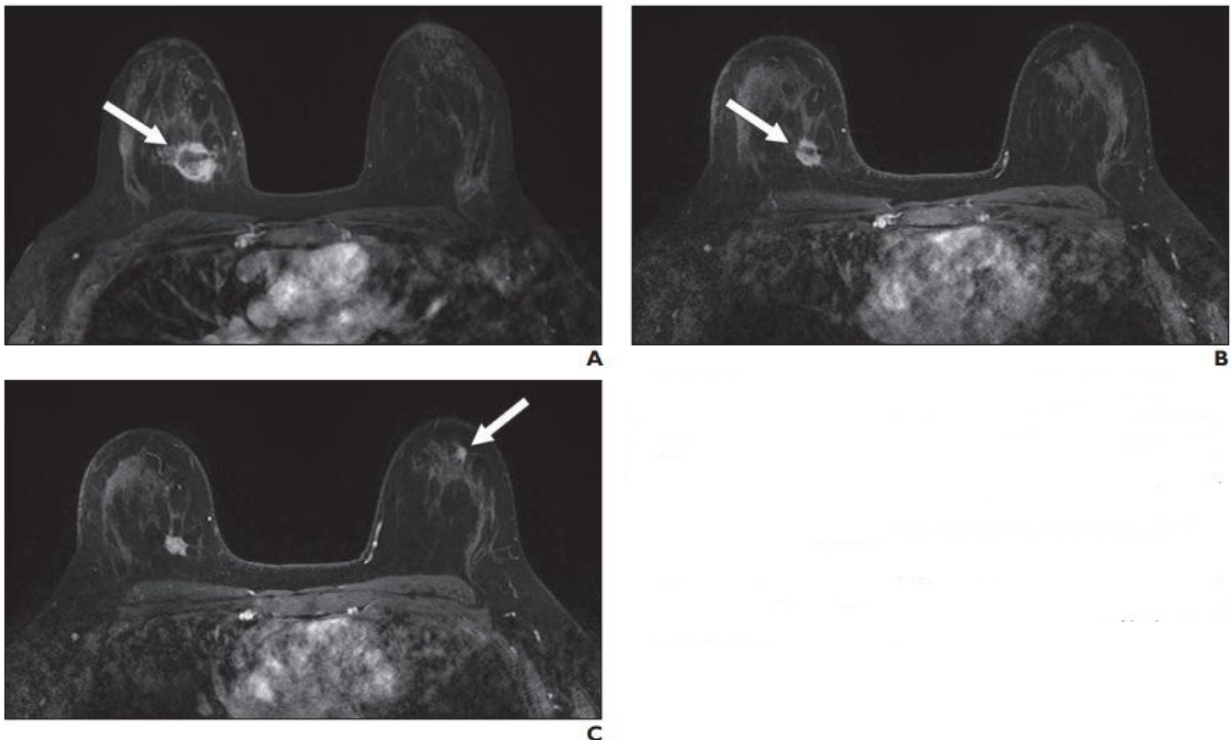


New suspicious lesions on breast MRI in neoadjuvant therapy

January 14 2021



A, Contrast-enhanced axial T1-weighted fat-saturated image from baseline MRI before initiation of neoadjuvant therapy shows irregular mass (arrow) in upper inner right breast corresponding to biopsy-proven carcinoma. B, Contrast-enhanced axial T1-weighted fat-saturated image from follow-up MRI performed 3 months after initiation of neoadjuvant therapy shows decrease in size of right breast cancer (arrow). C, Contrast-enhanced axial T1-weighted fat-saturated image 3 months after initiation of neoadjuvant therapy shows new mass (arrow) in upper outer left breast that was assessed as BI-RADS 4. Pathologic examination from MRI-guided core biopsy of new suspicious mass revealed benign usual ductal hyperplasia. No atypia or malignancy was identified. Credit:

American Roentgen Ray Society (ARRS), *American Journal of Roentgenology* (AJR)

According to ARRS' *American Journal of Roentgenology* (AJR), new suspicious findings occurred in 5.5% of breast MRI examinations performed to monitor response to neoadjuvant therapy; none of these new lesions were malignant.

"Our findings suggest that new [lesions](#) that arise in the setting of neoadjuvant therapy are highly unlikely to represent a new site of malignancy, particularly if the index malignancy shows [treatment response](#)," wrote Donna A. Eckstein and colleagues in the department of radiology and biomedical imaging at the University of California, San Francisco.

Based on a presentation at the ARRS 2019 Annual Meeting, Honolulu, HI, the researchers' retrospective review pinpointed all breast MRI examinations performed to assess [response](#) to [neoadjuvant therapy](#) between 2010 and 2018. Cases with new suspicious lesions assessed as BI-RADS 4 or 5 and found after the initiation of neoadjuvant treatment were included. Meanwhile, exclusion criteria were cases with no pretreatment MRI, cases in which the suspicious lesion was present on the baseline MRI but remained suspicious, and cases with insufficient follow-up. Pathologic examination determined malignant outcomes, whereas benignity was established by pathologic examination, follow-up imaging, or both.

A total of 419 breast MRI examinations in 297 women (mean patient age, 45 years; range, 32-65 years) were performed to assess response to neoadjuvant treatment. After exclusions, 23 MRI examinations (5.5%) with new suspicious findings distinct from the site of known malignancy

comprised the final study cohort. Of these 23 lesions, 13 new suspicious findings (56.5%) were contralateral to the known malignancy, nine (39.1%) were ipsilateral, and one (4.3%) involved the bilateral breasts. Lesion types included mass (16, 69.6%), nonmass enhancement (5, 21.7%), and focus (2, 8.7%).

Noting that, currently, there are no guidelines for the management of new suspicious imaging findings identified on MRI during the course of [neoadjuvant](#) systemic [breast](#) cancer treatment, "results in this small cohort suggest that these new findings are highly likely to be benign, particularly in the setting of response to therapy, which may potentially obviate biopsies in these patients in the future," wrote Eckstein et al.

"However," the authors of this *AJR* article concluded, "larger studies across different facilities are needed to confirm whether biopsy may be safely averted in this scenario."

More information: Donna A. Eckstein et al, Frequency and Outcomes of New Suspicious Lesions on Breast MRI in the Setting of Neoadjuvant Therapy, *American Journal of Roentgenology* (2021). [DOI: 10.2214/AJR.20.22979](#)

Provided by American Roentgen Ray Society

Citation: New suspicious lesions on breast MRI in neoadjuvant therapy (2021, January 14) retrieved 30 March 2023 from <https://medicalxpress.com/news/2021-01-suspicious-lesions-breast-mri-neoadjuvant.html>

<p>This document is subject to copyright. Apart from any fair dealing for the purpose of private study or research, no part may be reproduced without the written permission. The content is provided for information purposes only.</p>
--