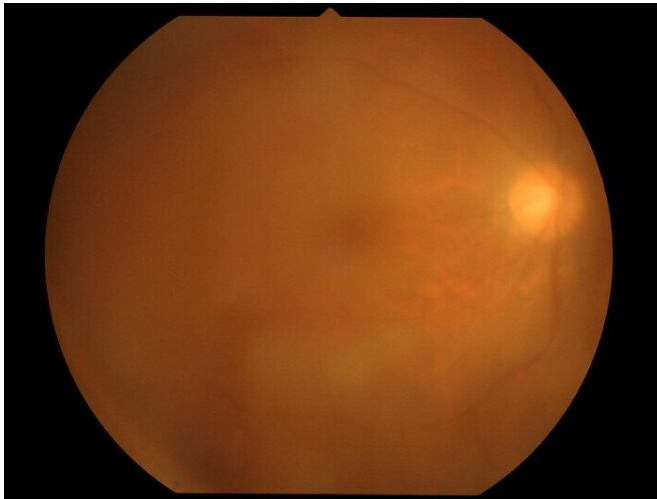


Horizontal HTLV-1 transmission can cause severe and persistent eye inflammation

27 April 2021



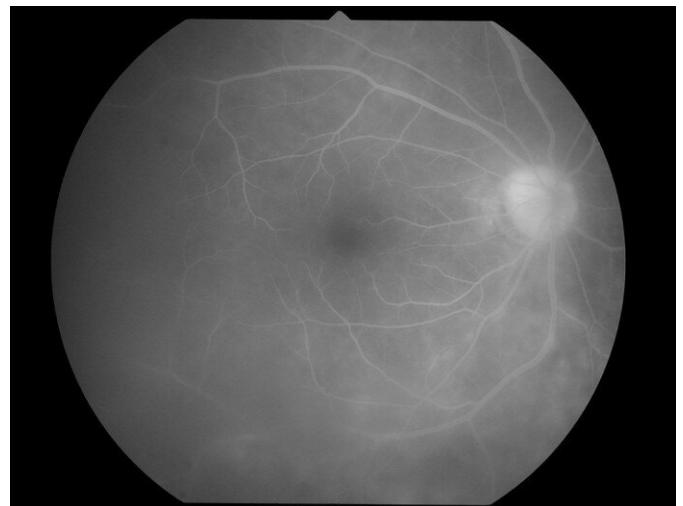
Vitreous opacity was observed by fundus imaging. Credit: Tokyo Medical and Dental University

Because the pathologies were consistent with uveitis and an inflammation of the eyes, and given the patient's age, the clinicians tested her for the presence of several autoimmune diseases, such as rheumatoid arthritis and sarcoidosis, because uveitis can be a result of those. The tests didn't reveal anything, so the clinicians tested the patient for a number of infectious diseases, such as HTLV-1 and HIV, that can also cause uveitis. When the HTLV-1 test came back positive, the clinicians made their diagnosis of HTLV-1 uveitis.

"HTLV-1 can cause adult T-cell lymphoma, myelopathy and uveitis, among other disorders," says senior author of the study Kyoko Ohno-Matsui. "Although we started the patient on the [proper treatment](#), an unanswered question was how did the patient get infected with the virus in the first place."

Human T-cell lymphotropic virus type-1 (HTLV-1) is a retrovirus similar to human immunodeficiency virus (HIV) and has mostly been thought to be transmitted vertically (mother-to-child), or horizontally (sexually or parenterally (e.g. via blood transfusion)). The spread of this infection in metropolitan areas such as Tokyo is presumed to be due to horizontal transmission, especially sexual transmission. HTLV-1-associated diseases are thought to be caused mainly through vertical transmission. In a new study, clinicians from Tokyo Medical and Dental University (TMDU) describe that horizontal transmission route is responsible for HTLV-1 associated disease, i.e. HTLV-1 uveitis.

The clinicians saw a 57-year-old woman who presented with sudden blurred vision. An [eye examination](#) revealed profound pathologies in different anatomical locations of her eyes. Most prominent were cellular infiltrates and opacity in the vitreous body, a large gel-like substance between the lens and the back of the eye.



Staining and leakage along the retinal vessel were observed by fluorescein angiography. Credit: Department of Ophthalmology and Visual Science, TMDU

Because there's no [targeted therapy](#) for HTLV-1

infections, the clinicians had to weaken the patient's immune system with corticosteroids, because an over-reacting immune system is thought to cause harm to the patient. The clinicians started the patient on corticosteroid therapy systemically as well as with topical eye drops over 6 weeks. Over the course of the next several months, the patient suffered from several recurrences, so the clinicians started her on a maintenance corticosteroid therapy, i.e. treatment over the course of 8 months. While no recurrences happened in this [time period](#), 18 months after the start of the maintenance therapy, the patient presented with another recurrence, including a [retinal detachment](#), which could lead to permanent blindness. This detachment was managed by ophthalmic surgery and the patient was again started on corticosteroids, this time for 4 years. No recurrences have happened since then and the patients has remained symptom-free.

Interestingly, during follow-up the patient's mother underwent cataract surgery at the same clinic site. Testing for HTLV-1 revealed no infection of the mother, ruling out vertical [transmission](#) to the patient. Of note, HTLV-1 can become symptomatic even decades after initial infection.

"In the current environment of increasing HTLV-1 incidence, the existence of horizontal transmission causing HTLV-1 uveitis should be acknowledged as it can result in more severe inflammation than vertical transmission. Thus, physicians should take the route of infection into consideration when providing medical care to patients with HTLV-1-associated diseases." says first / corresponding author of the study Koju Kamoi.

More information: Koju Kamoi et al, Horizontal transmission of HTLV-1 causing uveitis, *The Lancet Infectious Diseases* (2021). [DOI: 10.1016/S1473-3099\(21\)00063-3](#)

Provided by Tokyo Medical and Dental University
APA citation: Horizontal HTLV-1 transmission can cause severe and persistent eye inflammation (2021, April 27) retrieved 17 June 2021 from <https://medicalxpress.com/news/2021-04-horizontal-htlv-transmission-severe-persistent.html>

This document is subject to copyright. Apart from any fair dealing for the purpose of private study or research, no part may be reproduced without the written permission. The content is provided for information purposes only.