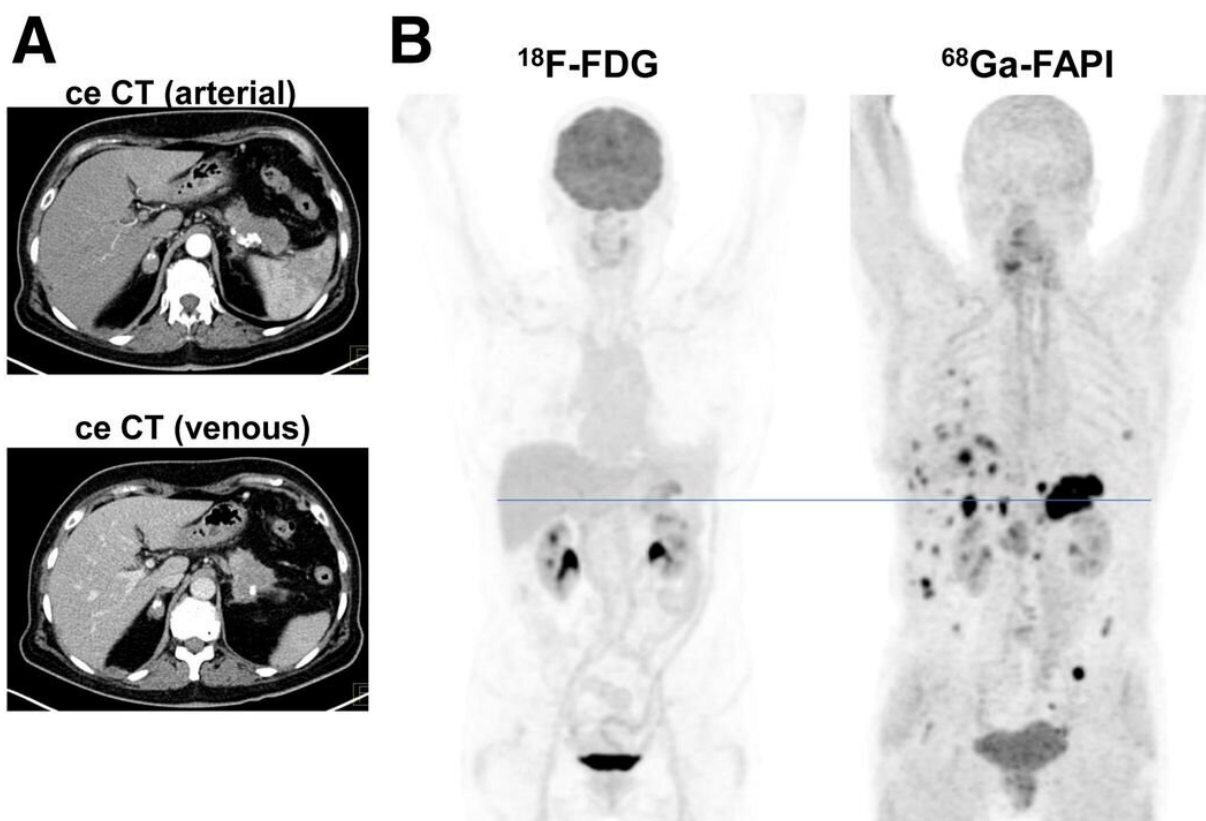


Molecular imaging improves staging and treatment of pancreatic ductal adenocarcinomas

July 7 2021



Primary staging of a patient with PDAC. (A) Axial images of PDAC and liver in arterial (upper image) and venous (lower image) ceCT scan. (B) Mean intensity projection (MIP) images of ^{18}F -FDG and FAPI PET/CT imaging. (C) Axial ^{18}F -FDG and FAPI PET/CT images of same patient on level (blue line in A) of pancreatic tumor mass and another suspicious FAPI accumulation in projection on perihepatic lymph node. Metastatic situation, which had been revealed by

FAPI PET/CT, was confirmed by biopsy of pulmonary lesion that was diagnosed as metastasis of known PDAC. Credit: Society of Nuclear Medicine and Molecular Imaging

For patients with pancreatic ductal adenocarcinomas (PDAC), molecular imaging can improve staging and clinical management of the disease, according to research published in the June issue of *The Journal of Nuclear Medicine*. In a retrospective study of PDAC patients, the addition of PET/CT imaging with 68Ga-FAPI led to restaging of disease in more than half of the patients, most notably in those with local recurrence.

PDAC is a highly lethal cancer, with a five-year survival rate of less than 10 percent. Optimal imaging of PDAC is crucial for accurate initial TNM (tumor, node, metastases) staging and selection of the primary treatment. Follow-up imaging is also important to accurately detect local recurrence or metastatic spread as early and as completely as possible.

"Currently, contrast-enhanced CT is the gold standard when it comes to TNM staging, and PET imaging isn't typically part of the clinical routine" stated Manuel Röhrich, MD, nuclear medicine physician at Heidelberg University Hospital in Heidelberg, Germany. "However, we know that PDAC is composed of certain fibroblasts that express fibroblast activation protein, which can be imaged with the novel PET radiotracer 68Ga-FAPI. Given this characteristic, we sought to explore the utility of 68Ga-FAPI PET/CT to image PDAC patients."

The study included 19 PDAC patients who received contrast-enhanced CT imaging followed by 68Ga-FAPI PET/CT. Results from the 68Ga-FAPI PET/CT scans were then compared with TNM staging based on contrast-enhanced CT. Changes in oncological management were

recorded.

68Ga-FAPI PET/CT-based TNM staging differed from contrast-enhanced CT imaging in 10 out of 19 patients, which resulted in changes in TNM staging. Of the 12 patients with recurrent disease, eight were upstaged, one was downstaged and three remained the same. In the seven patients newly diagnosed with PDAC, one was upstaged, while the staging remained the same for six of the [patients](#).

"This analysis suggests that 68Ga-FAPI PET/CT is a promising new imaging modality in staging of PDAC that may help to detect new or clarify inconclusive results obtained by standard CT imaging," said Röhrich. He added, "Improvement in survival can only be achieved by effective treatment approaches customized to the individual patient's disease status. Thus, hybrid imaging using FAPI tracer may open up new applications in staging and restaging of PDAC."

More information: Manuel Röhrich et al, Impact of 68Ga-FAPI PET/CT Imaging on the Therapeutic Management of Primary and Recurrent Pancreatic Ductal Adenocarcinomas, *Journal of Nuclear Medicine* (2020). [DOI: 10.2967/jnumed.120.253062](https://doi.org/10.2967/jnumed.120.253062)

Provided by Society of Nuclear Medicine and Molecular Imaging

Citation: Molecular imaging improves staging and treatment of pancreatic ductal adenocarcinomas (2021, July 7) retrieved 3 May 2023 from <https://medicalxpress.com/news/2021-07-molecular-imaging-staging-treatment-pancreatic.html>

<p>This document is subject to copyright. Apart from any fair dealing for the purpose of private study or research, no part may be reproduced without the written permission. The content is provided for information purposes only.</p>
--