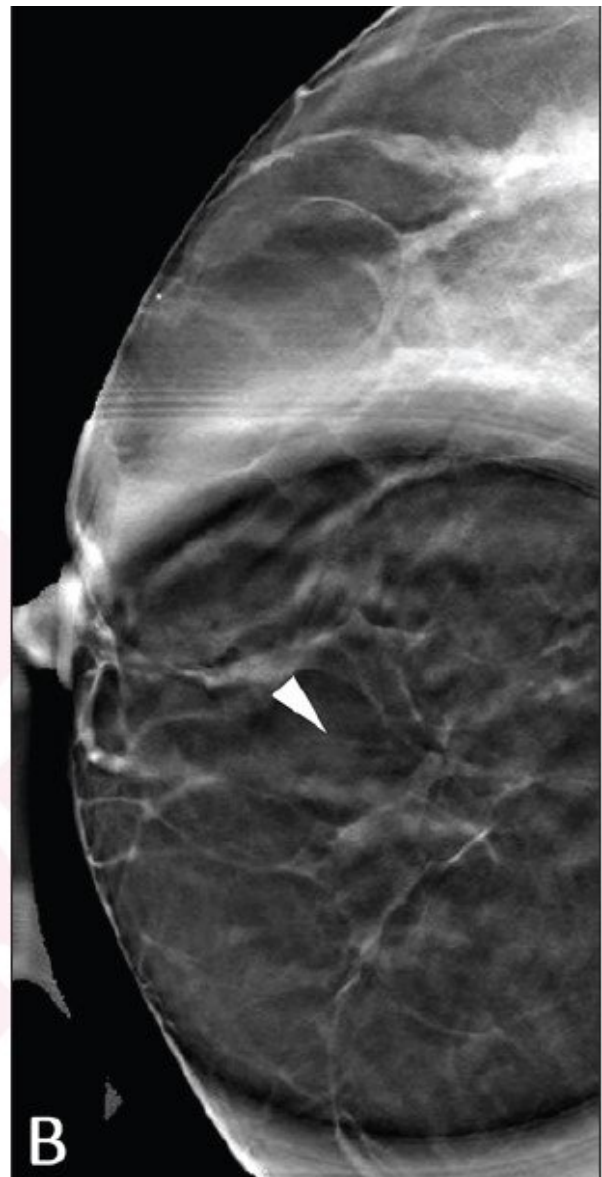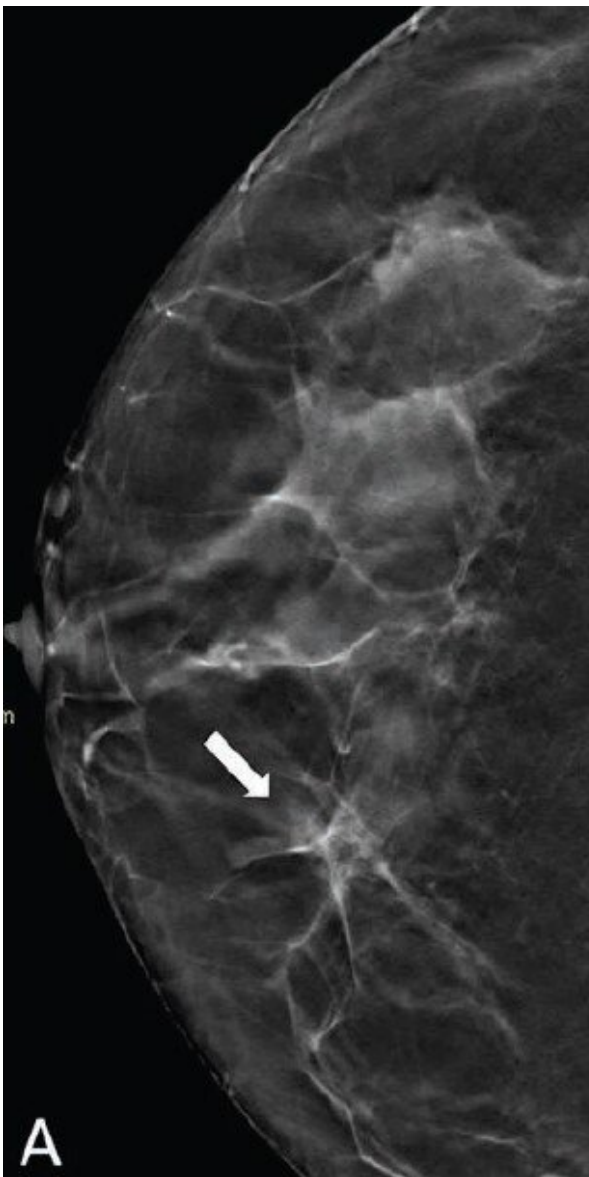


Digital breast tomosynthesis spot compression clarifies ambiguous DBT findings

February 16 2022



(A) DBT craniocaudal view shows asymmetry (arrow) in medial right breast (DBT). (B) DBT spot compression view shows asymmetry does not persist (arrowhead). Lesion classified on DBT without, and DBT with, DBT spot compression view as BI-RADS category 4a and 2 by reader 1, category 4a and 2 by reader 2, and category 4b and 2 by reader 3. Follow-up imaging at one year demonstrated stability of finding, consistent with benignity in present analysis. Credit: American Roentgen Ray Society (ARRS), *American Journal of Roentgenology*

According to an article in ARRS' *American Journal of Roentgenology* (*AJR*), digital breast tomosynthesis (DBT) spot compression view could help characterize equivocal DBT findings, thus reducing further workup for benign findings.

Noting that DBT spot compression increased both intrareader and interreader agreement and improved diagnostic accuracy, primarily from improved specificity, "the view's supplemental dose was slightly higher than that of a standard DBT view," corresponding author Foucauld Chamming's of Institut Bergonié in Bordeaux, France acknowledged.

The all-French team's retrospective study included 102 women (mean age, 60 years) for whom a DBT spot compression was acquired to characterize an equivocal finding on DBT (via the performing radiologist's discretion) from December 14, 2018 to December 18, 2019. Conscious of the equivocal lesions' location, two fellowship-trained breast radiologists and one breast imaging fellow independently reviewed all examinations—assigning an initial BI-RADS category using standard DBT views, immediately followed by a category using DBT spot compression.

Based on kappa coefficients for DBT with and without spot compression

views, intrareader agreement increased from 0.43 to 0.72, and interreader agreement increased from 0.21 to 0.45. Additionally, for all three readers, DBT spot compression views yielded significantly increased accuracy, as well as significantly increased specificity.

Adding that their study is the first to evaluate the impact of obtaining DBT spot compression for equivocal findings on DBT, "the results support the utility of spot [compression](#) views for aiding evaluation of subtle or ambiguous findings encountered on DBT in [clinical practice](#)," the authors of this *AJR* article concluded.

More information: F. Deleau et al, Impact of Obtaining a Digital Breast Tomosynthesis (DBT) Spot Compression View on Assessment of Equivocal DBT Findings, *American Journal of Roentgenology* (2022). [DOI: 10.2214/AJR.21.27190](https://doi.org/10.2214/AJR.21.27190)

Provided by American Roentgen Ray Society

Citation: Digital breast tomosynthesis spot compression clarifies ambiguous DBT findings (2022, February 16) retrieved 19 November 2023 from <https://medicalxpress.com/news/2022-02-digital-breast-tomosynthesis-compression-ambiguous.html>

<p>This document is subject to copyright. Apart from any fair dealing for the purpose of private study or research, no part may be reproduced without the written permission. The content is provided for information purposes only.</p>
