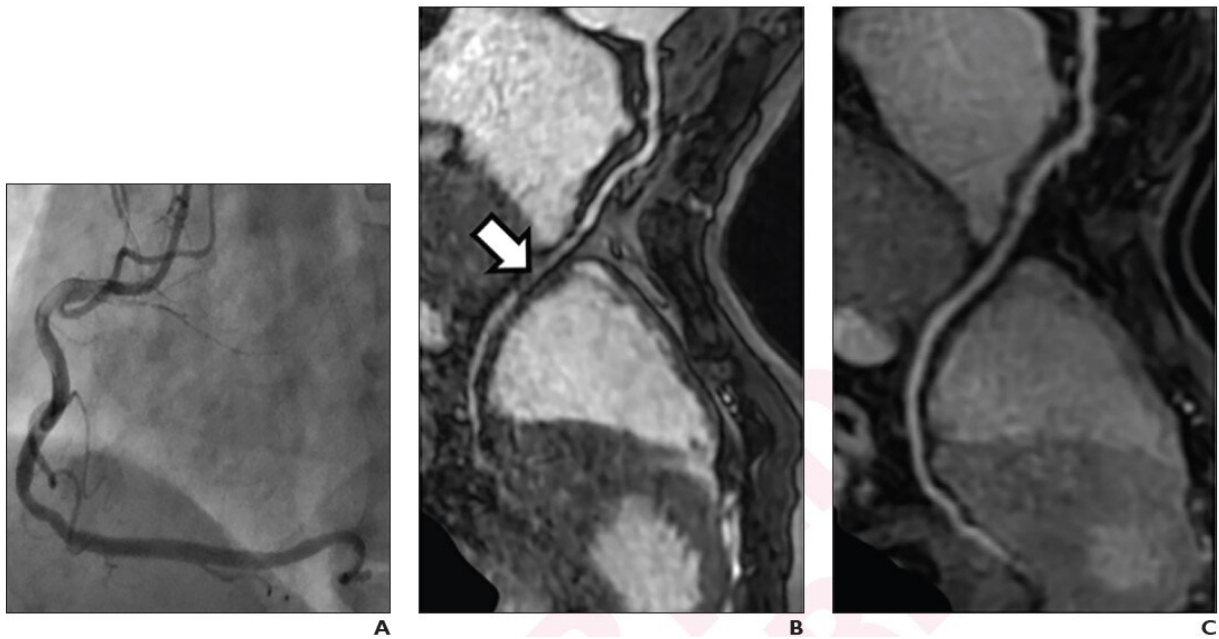


# Dixon GRE technique outperforms clinical standard for unenhanced coronary MRA

March 28 2022



(A) Image from coronary angiogram shows no significant stenosis of right coronary artery (RCA). (B) Curved multiplanar reformatted image from 1.5-T SSFP coronary MRA shows severe stenosis of mid RCA (arrow), representing a false-positive finding. (C) Curved multiplanar reformatted image from 3-T Dixon GRE coronary MRA shows no RCA stenosis. Credit: American Roentgen Ray Society, *American Journal of Roentgenology*

According to ARRS' *American Journal of Roentgenology (AJR)*, the 3-T Dixon gradient-recalled echo (GRE) sequence performed higher than the

current standard of 1.5-T SSFP for unenhanced coronary MRA, which could help expand clinical adoption of the procedure.

"For unenhanced coronary MRA, 3-T unenhanced Dixon GRE had better image quality and diagnostic performance than 1.5-T SSFP, particularly for distal and branch segments," wrote lead researcher Hang Jin from China's Fudan University and Shanghai Institute of Medical Imaging.

Jin and team's prospective study included 44 patients (27 men, 17 women; mean age, 59 years) with intermediate-to-high risk of coronary artery disease who underwent both 1.5-T SSFP and 3-T Dixon GRE coronary MRA examinations before [coronary angiography](#). Two [radiologists](#) independently assessed coronary arteries in random order for subjective image quality, number of visible segments, apparent contrast-to-[noise ratio](#), and presence of significant stenoses.

Compared with 1.5-T SSFP, coronary MRA using 3-T unenhanced Dixon GRE demonstrated higher image quality ( $4.0 \pm 1.1$  vs  $3.0 \pm 1.2$ ), higher percentage of visible coronary segments (96.7% vs 88.9%), as well as higher sensitivity (87.9% vs 77.3%) and specificity (83.3% vs 60.6%) for significant stenoses on a per-vessel basis, using coronary angiography as reference.

"The present results demonstrate the benefits of robust epicardial fat suppression using Dixon GRE in terms of improved apparent contrast-to-noise and improved visibility, with the latter difference observed particularly for distal and branch segments that course close to the myocardium," the authors of this *AJR* article concluded.

**More information:** Di Tian et al, Unenhanced Whole-Heart Coronary MRA: Prospective Intraindividual Comparison of 1.5-T SSFP and 3-T Dixon Water-Fat Separation GRE Methods Using Coronary

Angiography as Reference, *American Journal of Roentgenology* (2022).  
[DOI: 10.2214/AJR.21.27292](https://doi.org/10.2214/AJR.21.27292)

Provided by American Roentgen Ray Society

Citation: Dixon GRE technique outperforms clinical standard for unenhanced coronary MRA (2022, March 28) retrieved 5 February 2024 from  
<https://medicalxpress.com/news/2022-03-dixon-gre-technique-outperforms-clinical.html>

This document is subject to copyright. Apart from any fair dealing for the purpose of private study or research, no part may be reproduced without the written permission. The content is provided for information purposes only.